Endovascular treatment of ruptured pararenal aneurysms using chimneys

Miltos Matsagkas MD, PhD, FEBVS
Professor of Vascular Surgery
University of Thessaly, Greece

Ch-EVAR for pararenal AAAs

An established endovascular approach

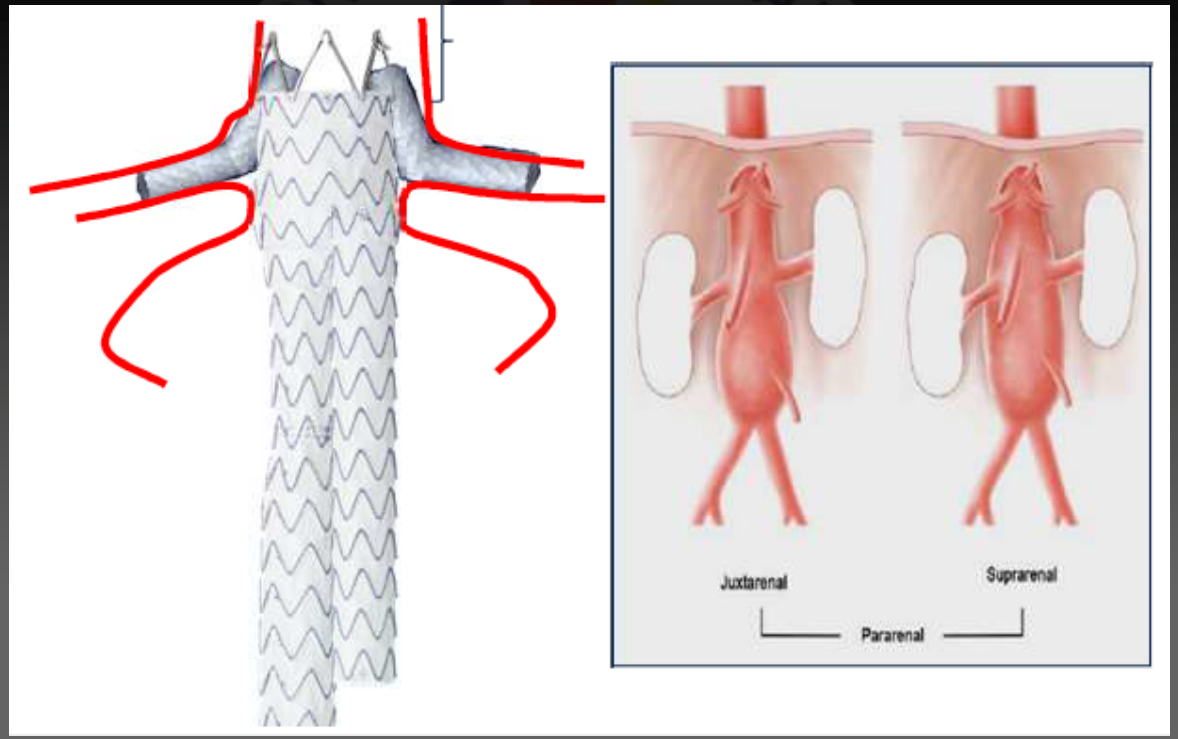

Larissa University Hospital, Greece

- From 5/2016-5/2022 (mean Fup **36 months, range 0-72 months**)
- **67** Ch-EVAR
  - *6 for rupture*
- **136** target vessels
- **22** x3 chimneys, **25** x2 chimneys, **20** x1 chimney
- **12** pts had previous aortic surgery (11 pts with failed EVAR & 1 with anastomotic aneurysm after OR)
- **51** Endurant (Medtronic), **10** Nellix (Endologix), **5** Incraft (Cordis), **1** Bolton Relay (Terumo Aortic)

Larissa University Hospital, Greece

Technical success: 100%

30-day mortality: 8.9% - 6/67 pts

- ✓ 4 aneurysm related deaths
  - ✓ 1 SIRS (chimneys patent)
  - ✓ 1 graft and chimney thrombosis
  - ✓ 1 MOD after hypovolemic shock
  - ✓ Hypovolemic shock in a ruptured case
- ✓ 2 MIs (previous history of CAD)

Preliminary results published in 2019

Volume 1 Issue 2 April 2019 ISSN 1106-7237

Hellenic Society of Vascular and Endovascular Surgery

Hellenic Journal of Vascular and Endovascular Surgery

HOT TOPICS

www.heljves.com

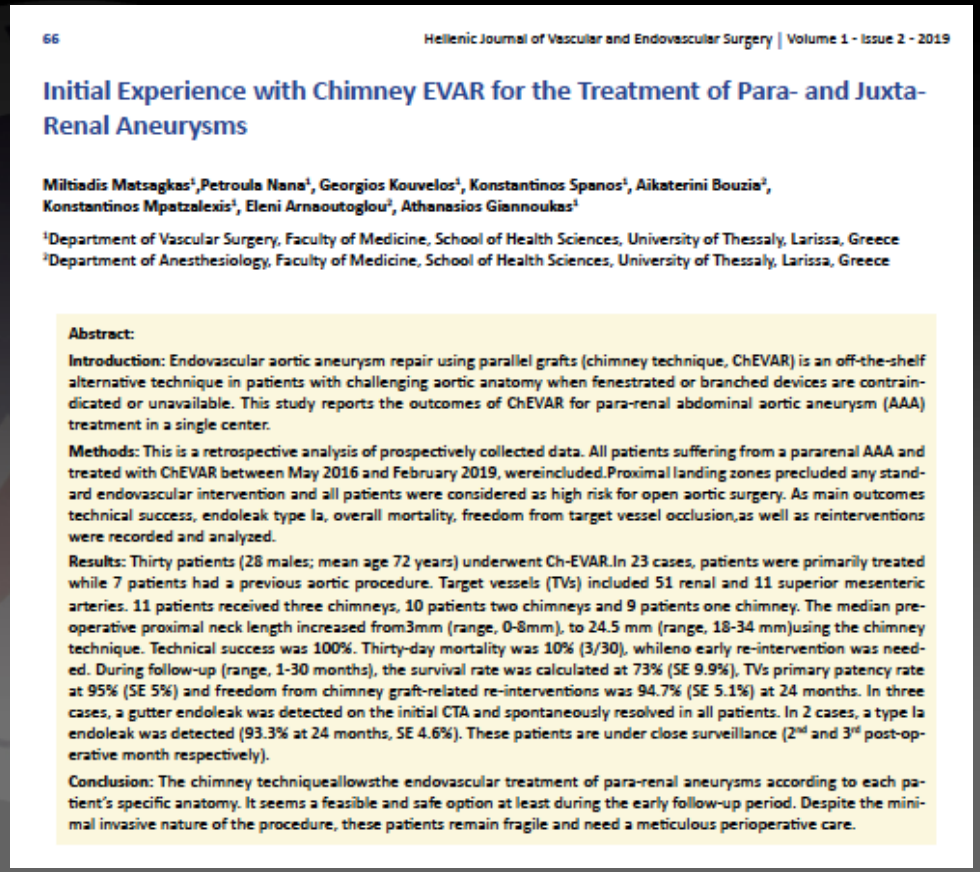

Initial Experience with Chimney EVAR for the Treatment of Para- and Juxta-Renal Aneurysms

Miltiadis Matsagkas[1], Petroula Nana[1], Georgios Kouvelos[1], Konstantinos Spanos[1], Aikaterini Bouzia[2], Konstantinos Mpatzalexis[1], Eleni Arnaoutoglou[2], Athanasios Giannoukas[1]

[1]Department of Vascular Surgery, Faculty of Medicine, School of Health Sciences, University of Thessaly, Larissa, Greece
[2]Department of Anesthesiology, Faculty of Medicine, School of Health Sciences, University of Thessaly, Larissa, Greece

Abstract:

Introduction: Endovascular aortic aneurysm repair using parallel grafts (chimney technique, ChEVAR) is an off-the-shelf alternative technique in patients with challenging aortic anatomy when fenestrated or branched devices are contraindicated or unavailable. This study reports the outcomes of ChEVAR for para-renal abdominal aortic aneurysm (AAA) treatment in a single center.

Methods: This is a retrospective analysis of prospectively collected data. All patients suffering from a pararenal AAA and treated with ChEVAR between May 2016 and February 2019, wereincluded.Proximal landing zones precluded any standard endovascular intervention and all patients were considered as high risk for open aortic surgery. As main outcomes technical success, endoleak type Ia, overall mortality, freedom from target vessel occlusion,as well as reinterventions were recorded and analyzed.

Results: Thirty patients (28 males; mean age 72 years) underwent Ch-EVAR.In 23 cases, patients were primarily treated while 7 patients had a previous aortic procedure. Target vessels (TVs) included 51 renal and 11 superior mesenteric arteries. 11 patients received three chimneys, 10 patients two chimneys and 9 patients one chimney. The median preoperative proximal neck length increased from3mm (range, 0-8mm), to 24.5 mm (range, 18-34 mm)using the chimney technique. Technical success was 100%. Thirty-day mortality was 10% (3/30), whileno early re-intervention was needed. During follow-up (range, 1-30 months), the survival rate was calculated at 73% (SE 9.9%), TVs primary patency rate at 95% (SE 5%) and freedom from chimney graft-related re-interventions was 94.7% (SE 5.1%) at 24 months. In three cases, a gutter endoleak was detected on the initial CTA and spontaneously resolved in all patients. In 2 cases, a type Ia endoleak was detected (93.3% at 24 months, SE 4.6%). These patients are under close surveillance (2nd and 3rd post-operative month respectively).

Conclusion: The chimney techniqueallowsthe endovascular treatment of para-renal aneurysms according to each patient's specific anatomy. It seems a feasible and safe option at least during the early follow-up period. Despite the minimal invasive nature of the procedure, these patients remain fragile and need a meticulous perioperative care.

Enchant Study

- Prospective
- International
- Multi-center

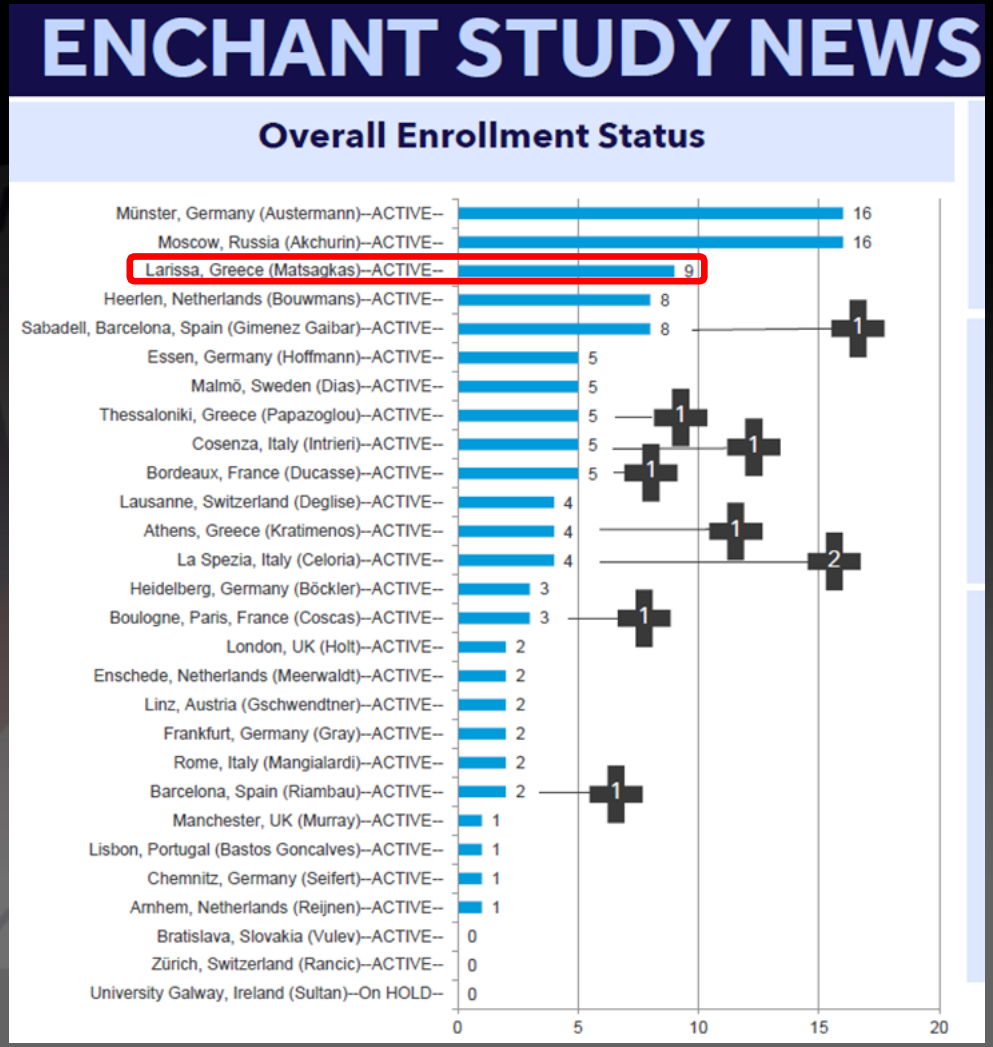

Open repair is not a good option for ruptured aneurysms



Guidelines

2017

SOCIETY FOR VASCULAR SURGERY® DOCUMENT

The Society for Vascular Surgery practice guidelines on the care of patients with an abdominal aortic aneurysm

CrossMark

If it is anatomically feasible, we recommend EVAR over open repair for treatment of a ruptured AAA.	
Level of recommendation	1 (Strong)
Quality of evidence	C (Low)

Guidelines

2019

Eur J Vasc Endovasc Surg (2019) 57, 8—93

Editor's Choice — European Society for Vascular Surgery (ESVS) 2019 Clinical Practice Guidelines on the Management of Abdominal Aorto-iliac Artery Aneurysms

Recommendation 74	Class	Level
In patients with ruptured abdominal aortic aneurysm and suitable anatomy, endovascular repair is recommended as a first option.	I	B

New data favor rEVAR

2020

Endovascular Repair of Ruptured Abdominal Aortic Aneurysm (rEVAR) is Superior to Open Surgical Repair (rOSR)

Propensity-Matched Analysis of VQI Database

724 pairs of rOSR and rEVAR after 1:1 matching

rEVAR		rOSR
5 days	Length of Stay P<.001	10 days
18%	30 Day Mortality P<.001	32%
35%	Major Adverse Event P<.001	68%
73%	1 Year Survival P<.001	59%

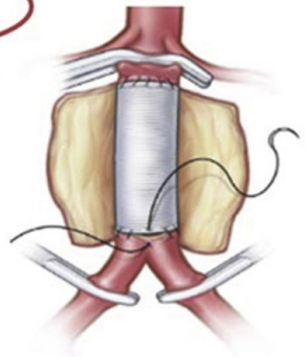

JVS Journal of Vascular Surgery
Official Publication of the Society for Vascular Surgery

Wang et al. *J Vasc Surg August 2020*

LinkedIn @TheJVascSurg @JVascSurg

Ruptured abdominal aortic aneurysm repair: introducing a step-by-step protocol

Miltiadis Matsagkas[1], George Kouvelos[1], Konstantinos Spanos[1], Aikaterini Bouzia[2], Eleni Arnaoutoglou[2], Athanasios Giannoukas[1]

[1]Department of Vascular Surgery, University of Thessaly, Medical School, Larissa, Greece
[2]Department of Anesthesiology, University of Thessaly, Medical School, Larissa, Greece

Volume 1 Issue 2 April 2019 ISSN 1106-7237

Hellenic Society of Vascular and Endovascular Surgery

Hellenic Journal of Vascular and Endovascular Surgery

HOT TOPICS

www.heljves.com

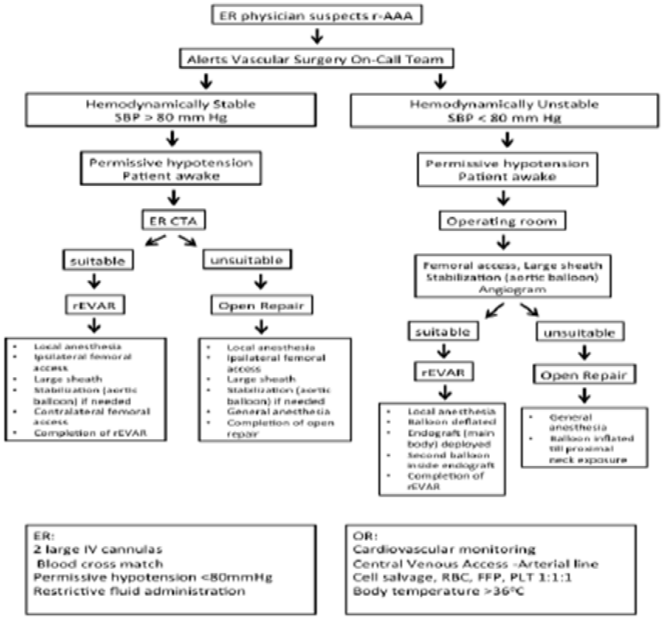

Figure 1. Summary of the protocol algorithm.

Complex neck AAA anatomy in ruptured AAAs

- ✓ Short neck (juxtrarenal, pararenal, suprarenal aneurysms)

+ / -

- ✓ Extreme angulation (>75^0)

ChEVAR is only for para-renal aneurysms

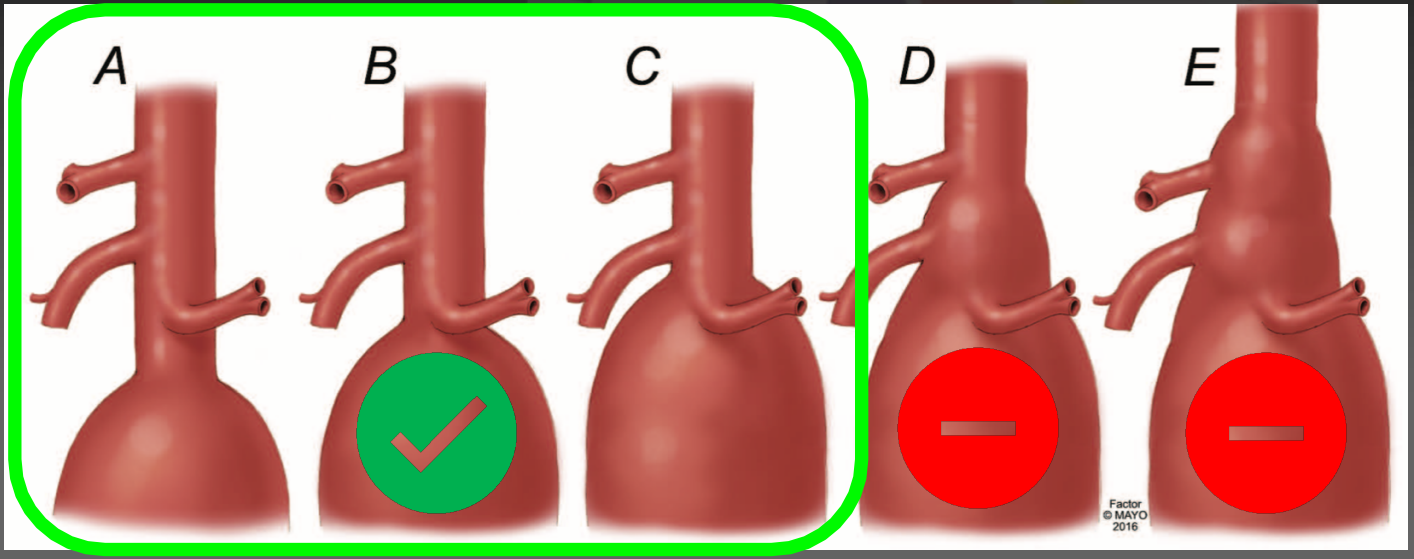

Endo solutions for para-renal AAA anatomy in ruptured cases

F-EVAR
Custom made



B-EVAR

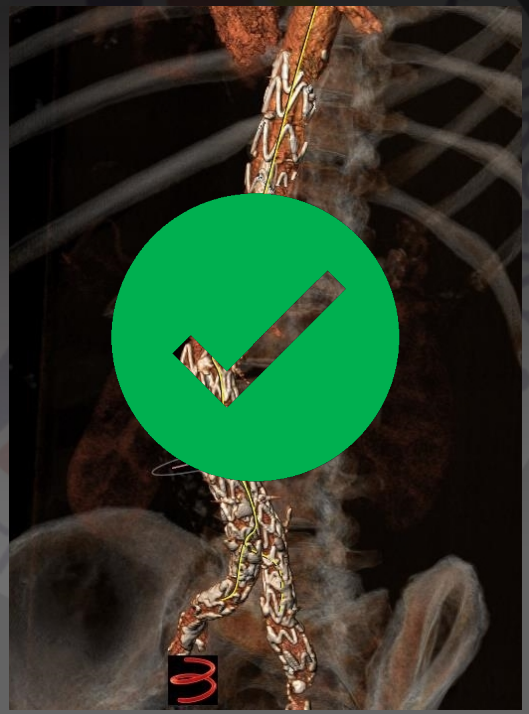

Ch-EVAR

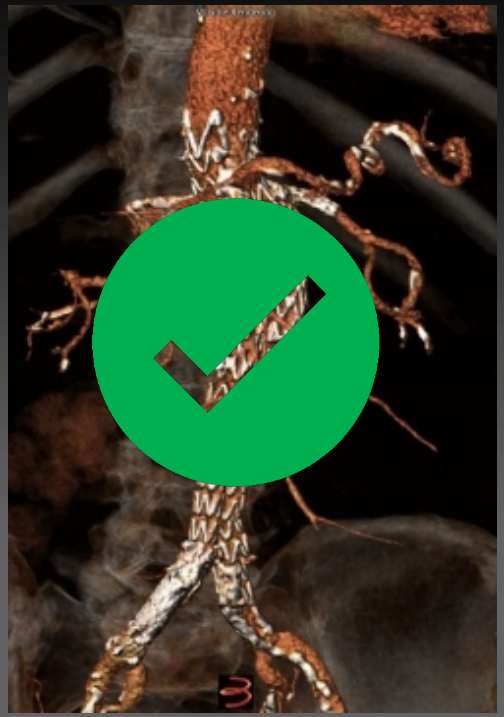

Ch-EVAR cover much less healthy aorta upwards

Ch-EVAR

Up to CA

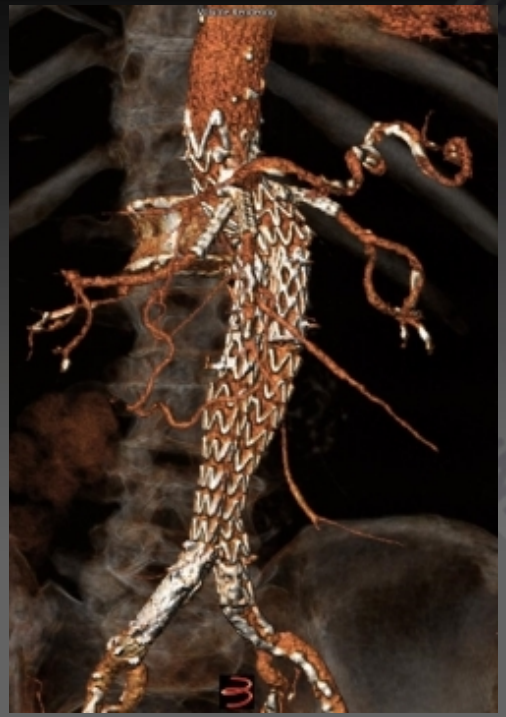

F-EVAR

3-5cm above CA



B-EVAR

10+cm above CA

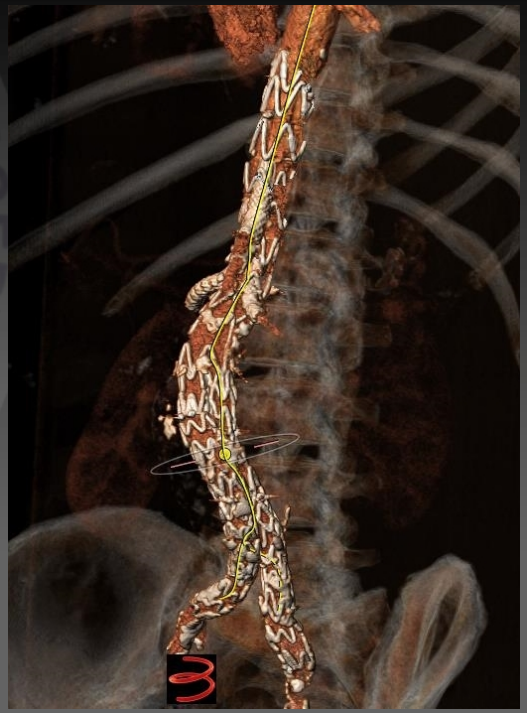

Suitable endovascular resources

- ✓ Experience
  (several cases in elective conditions)
- ✓ Imaging (adequate in lateral positions)
- ✓ Logistics (availability in a wide list of materials)

Ch-EVAR is not an easy task…



- ✓ Accuracy is essential when planning Ch-EVAR

New neck length

Our practice

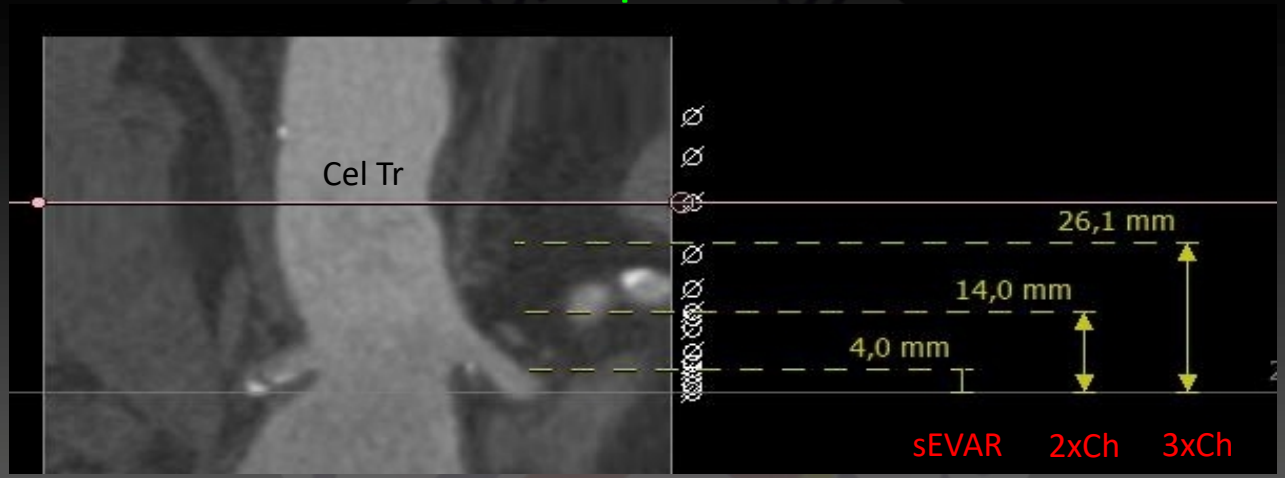

- ✓ Median pre-op proximal neck length: **3mm** (range, 0-8 mm)
- ✓ Median neck length after chimney: **21.5 mm** (range, 16-38 mm)

Oversizing

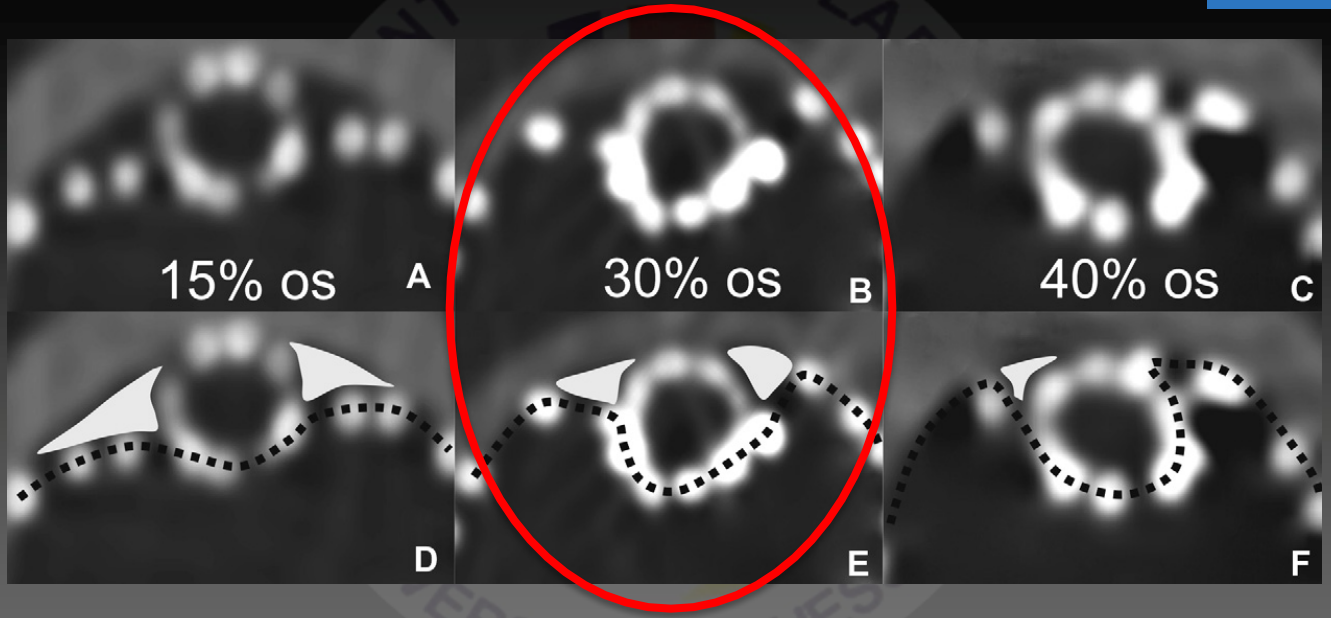

20-30% OVERSIZING

Mestres et al, Eur J Vasc Endovasc Surg 2012

Be aware of Ch-EVAR logistics!!

Materials:
what you need to perform a Chimney-EVAR

STENT-GRAFT

Excluder (Gore)

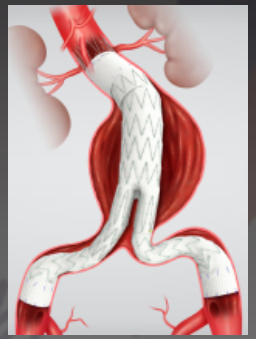

Zenith (Cook)

Nellix (Endologix)

Incraft (Cordis)

Materials:
what you need to perform a Chimney-EVAR

STENT-GRAFT

Endurant (Medtronic)

The **only** Stent-Graft system with **CE mark** for chimneys !!

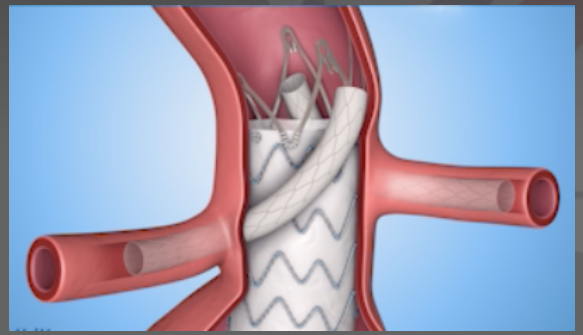

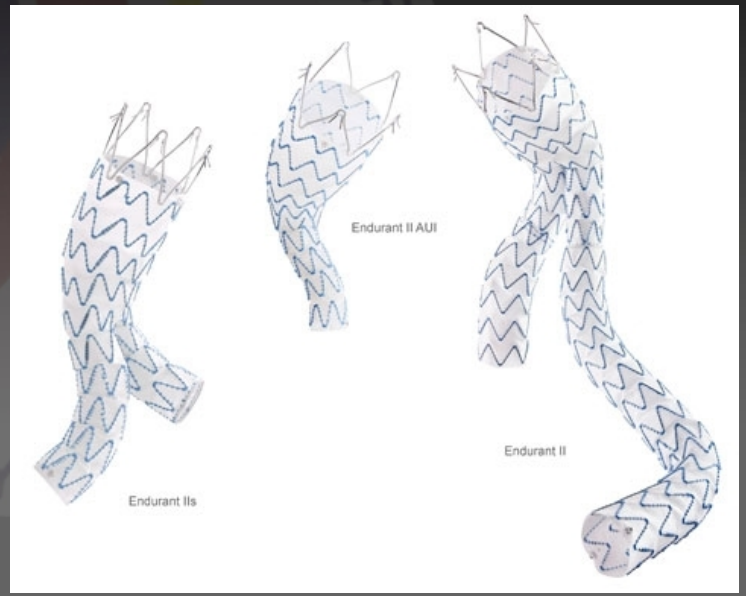

Materials:
what you need to perform a Chimney-EVAR

GUIDEWIRES

0.035 Standard



0.035 Hydrophilic

0.035 Extra-stiff



0.035 Super-stiff

0.035 special GW
for visceral arteries



Materials:
what you need to perform a Chimney-EVAR

SHEATHS FOR TARGET VESSELS



7-8Fr

Multipurpose (curved)

or straight

Always 70 or 90cm

Materials:
what you need to perform a Chimney-EVAR

OTHER SHEATHS

12-18Fr sheath
28-45 cm length
(in case of trombone technique)

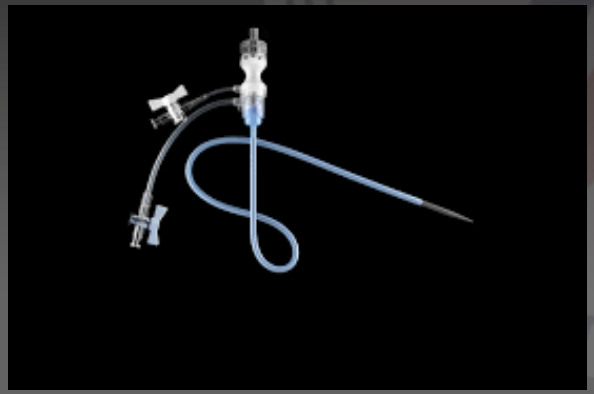

Materials:
what you need to perform a Chimney-EVAR

CATHETERS (Long 100-110 cm)

Headhunter



Vertebral



Simmons



Pigtail

Materials:
what you need to perform a Chimney-EVAR

Bx covered Stents

Advanta V12 (Macquet)

BeGraft+ (Bentley)

Viabahn VBX (Gore)

LifeStream (Bard)

Access vessels - Patient position

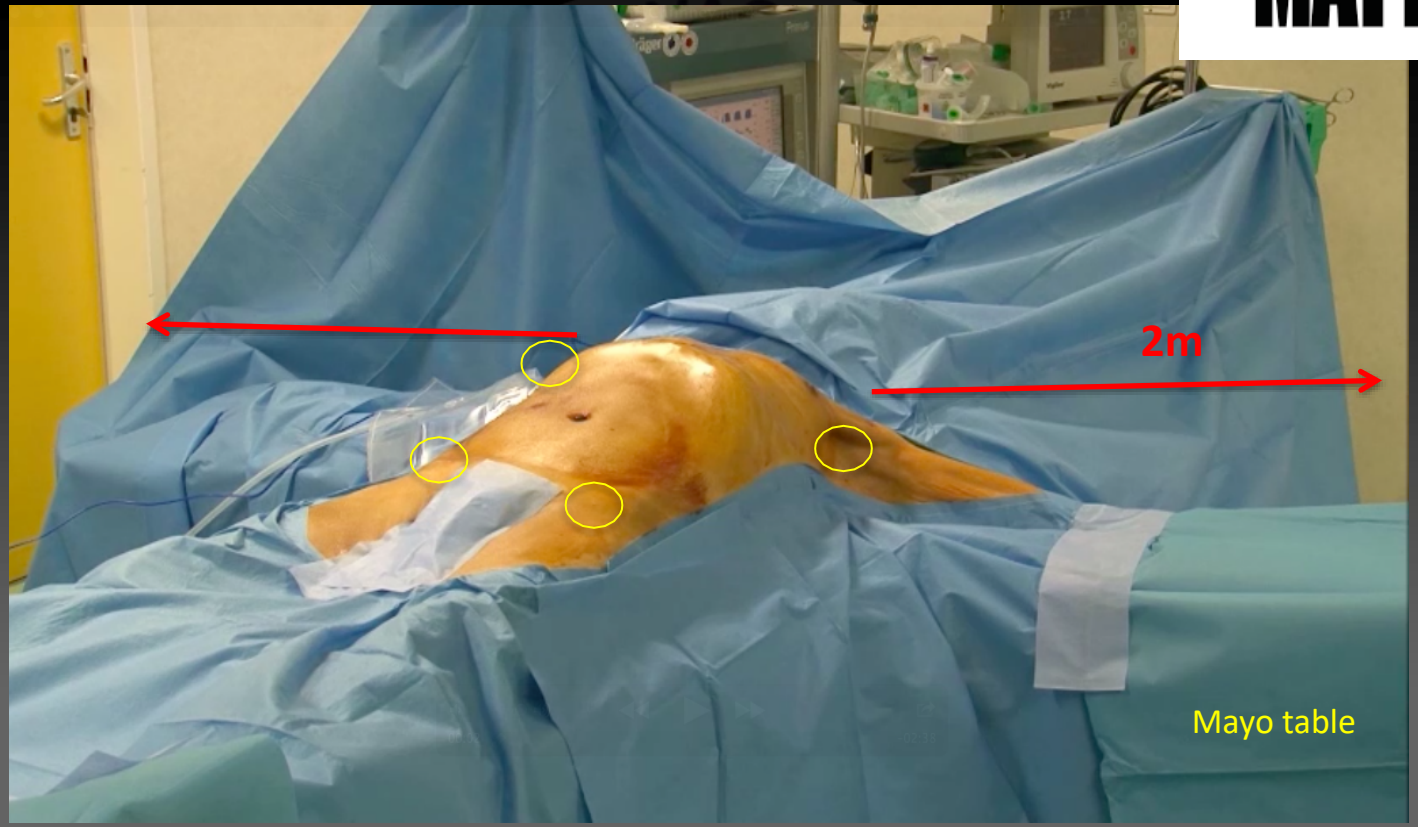

Suitable endovascular resources

Room and imaging

Suitable endovascular resources

Wide range of materials

Case 1

- 65 years old male patient, previous EVAR for AAA 8 years ago
- Abdominal and back pain starting 6 hours ago, addmited to district hospital, CTA: Ed Ia and AAA rupture
- Hemodynamicaly stable (mean AP 80mmHg), transferred to our Hospital
- On admission:
  - Fluid restriction, immediately transfer to OR
  - CTA evaluation
  - Local anesthesia, endovascular repair using Endurant stend-graft and one Chimney graft in LRA

Case 1

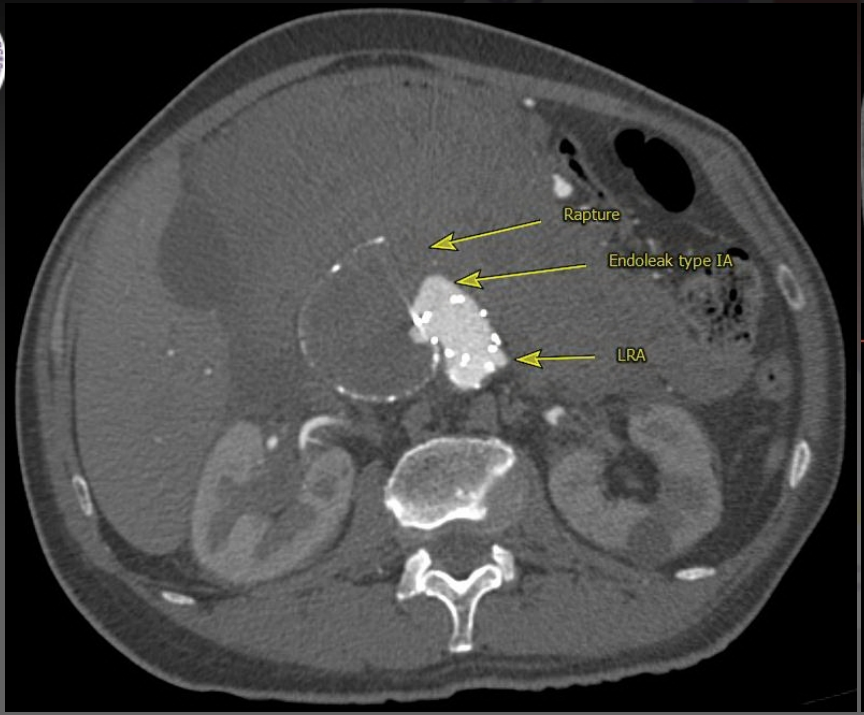

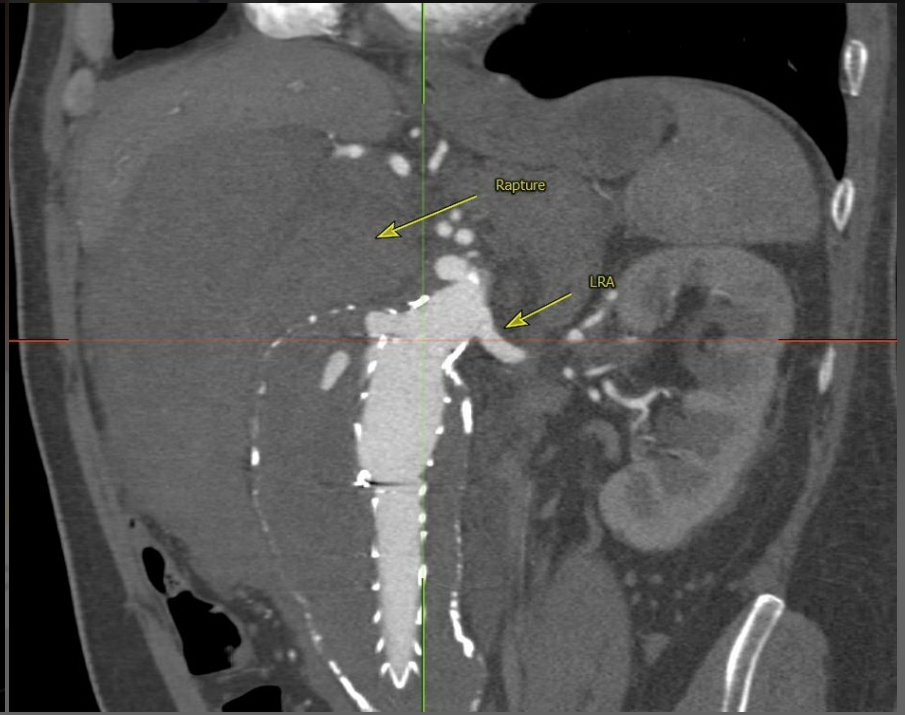

Case 1

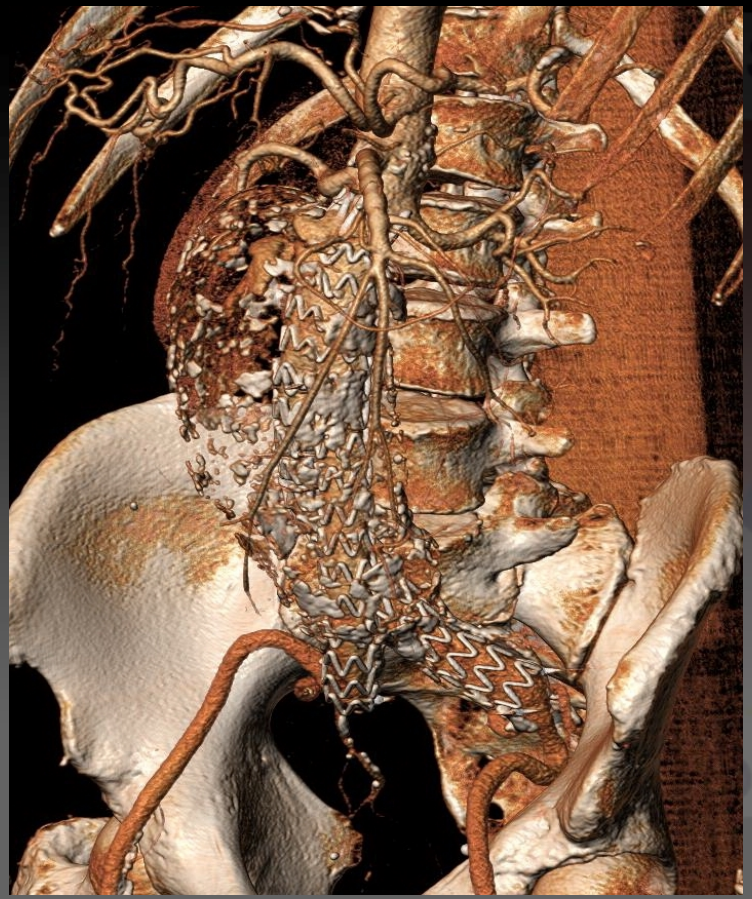

Case 1

Case 1

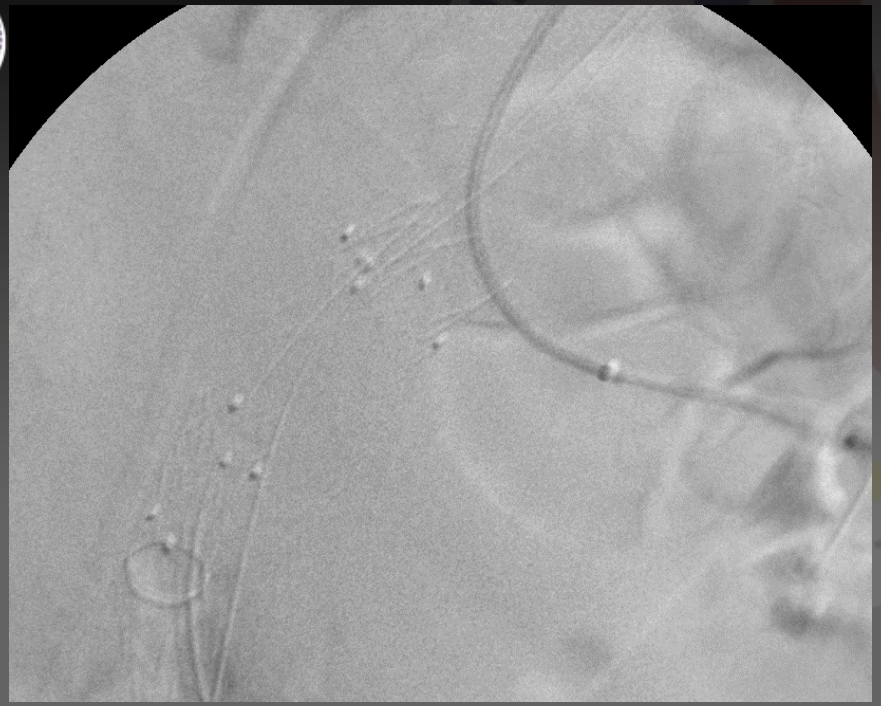

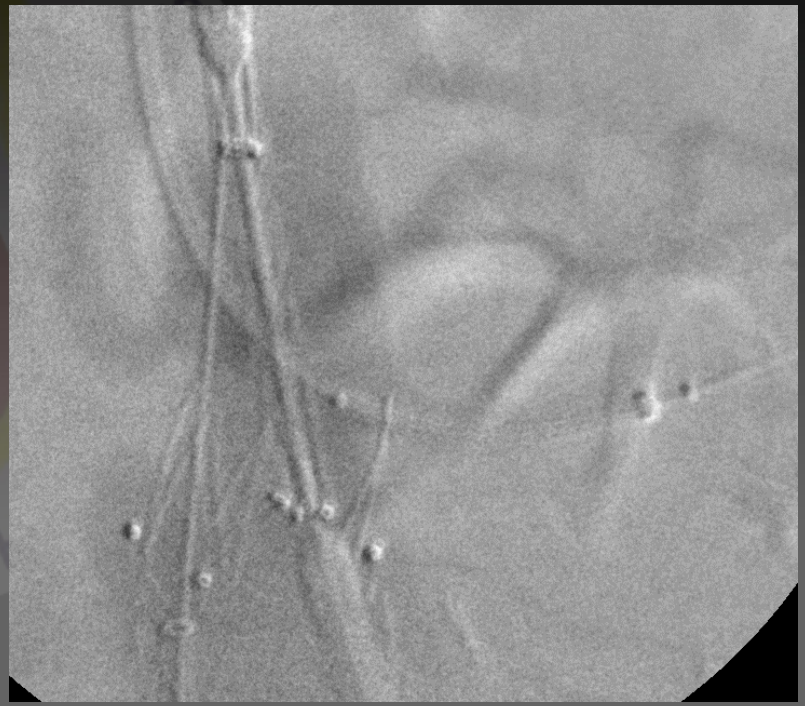

Case 1

Case 1

- Transferred to the wards
- Uneventful recovery
- Post-op CTA: ok, no endoleak
- Discharged home 3rd post-op day
- 2 years later he is living a normal life

Case 1

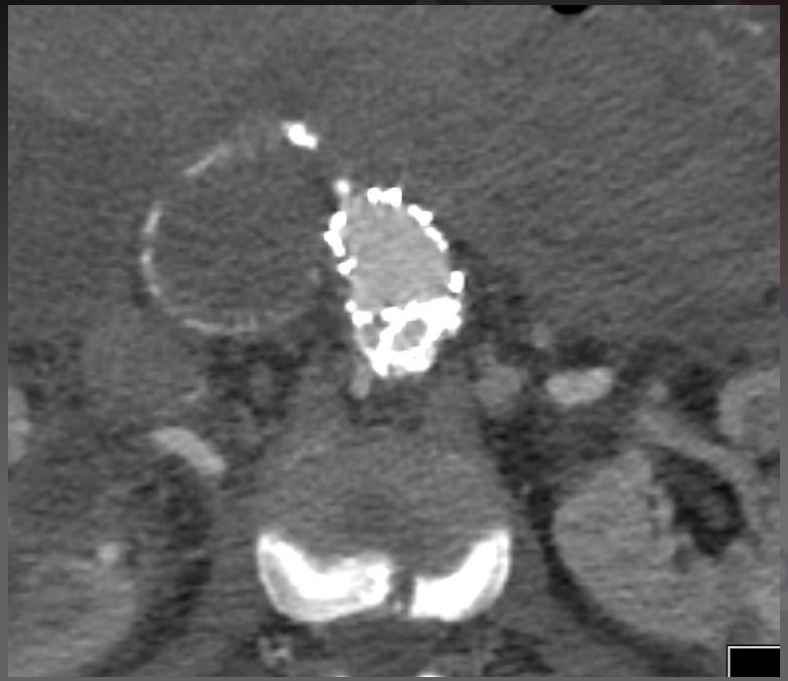

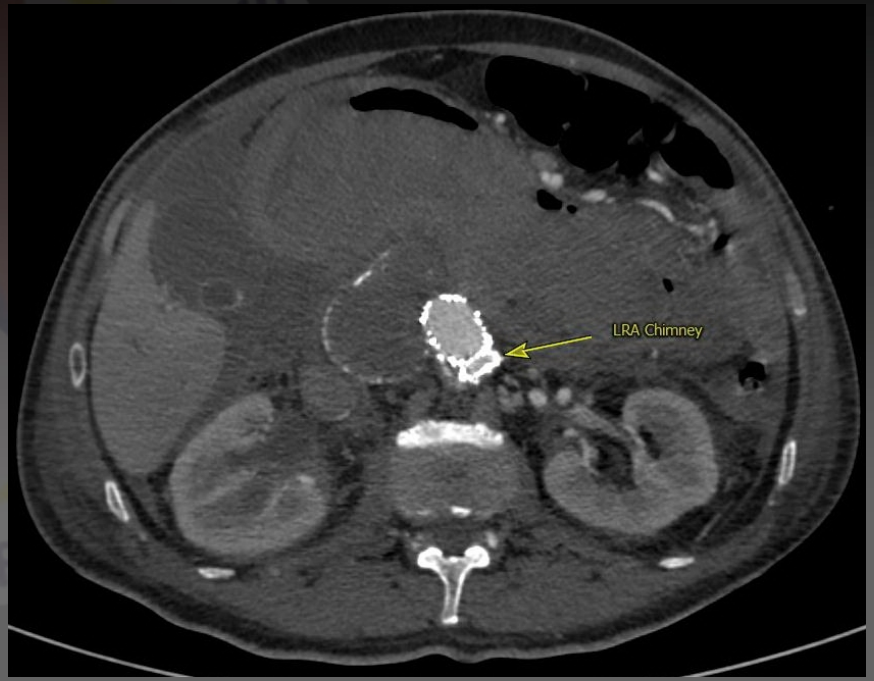

Case 1

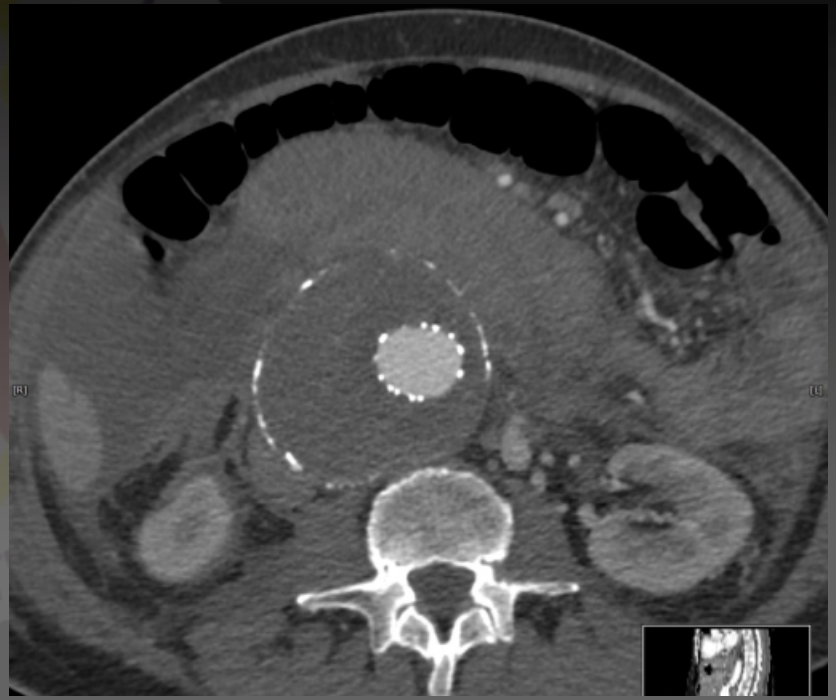

Case 1

Case 1

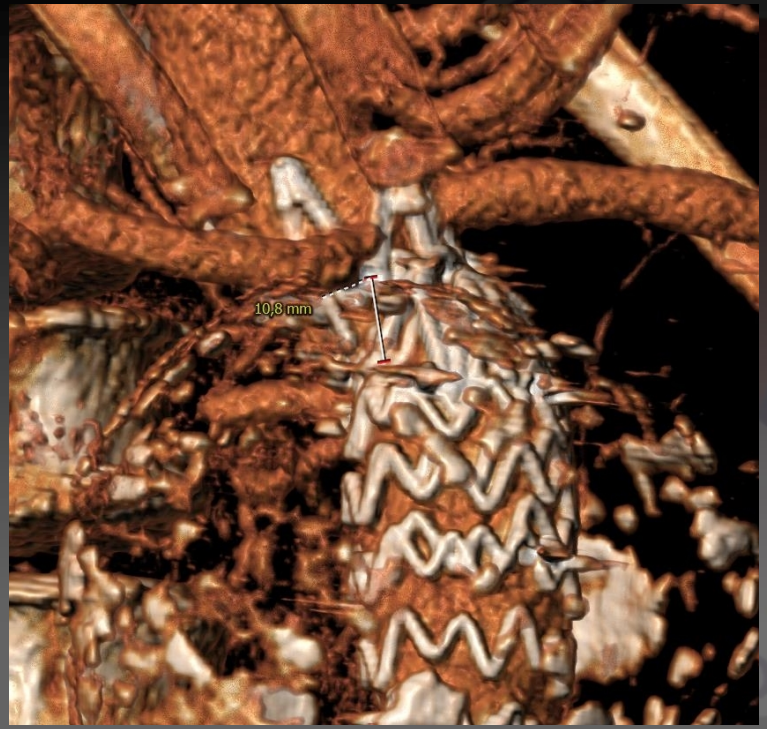

Case 2

- 62 years old male patient
- Abdominal and back pain starting 4 hours ago, presented to our hospital, CTA: pararenal AAA rupture
- Hemodynamicaly stable (mean AP 90mmHg)
- On admission:
  - Fluid restriction, immediately transfer to OR
  - CTA evaluation
  - Local anesthesia, endovascular repair using Endurant stend-graft and three Chimney grafts in LRA, RRA and SMA

Case 2

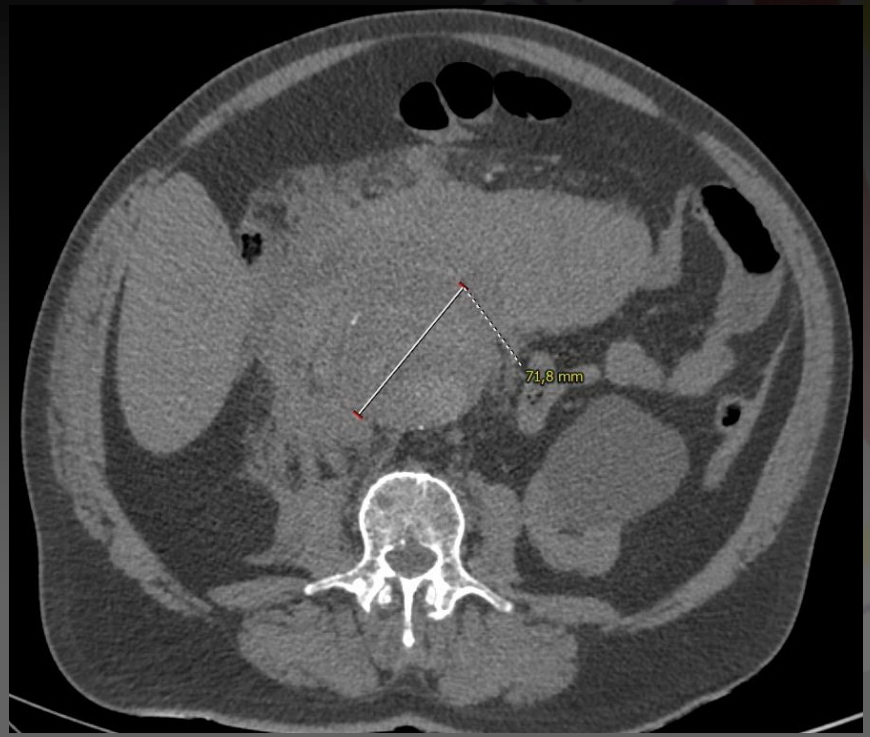

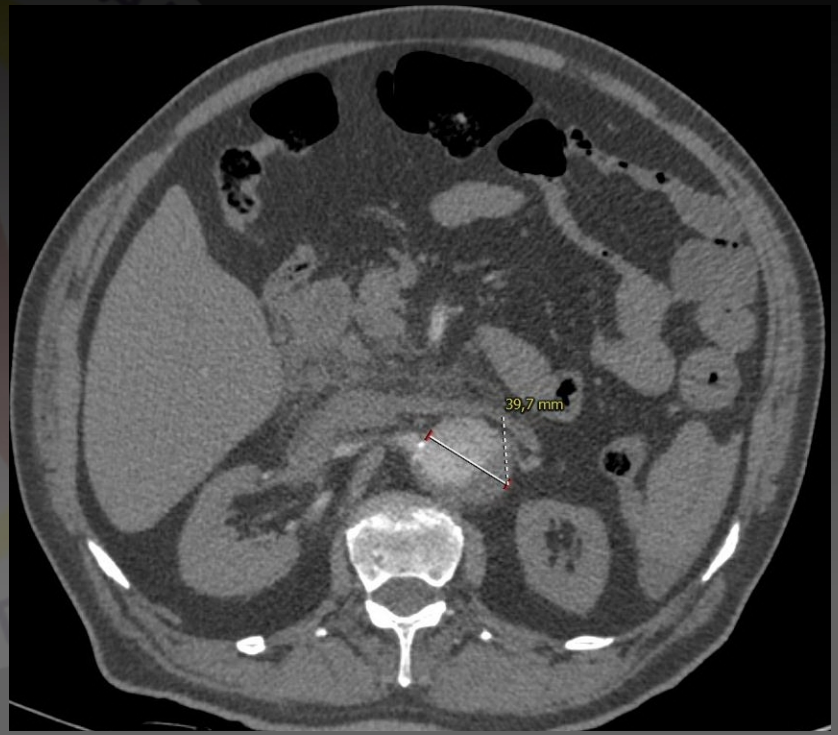

Case 2

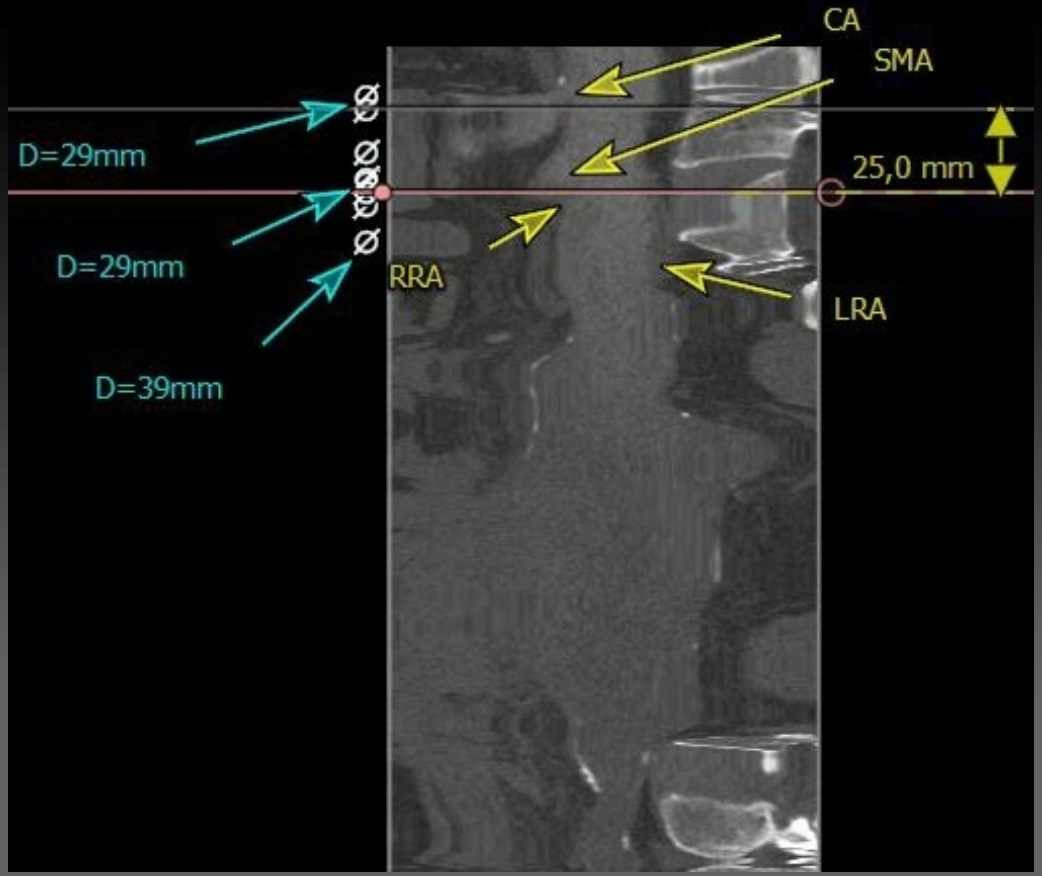

Case 2

LRA

RRA

SMA

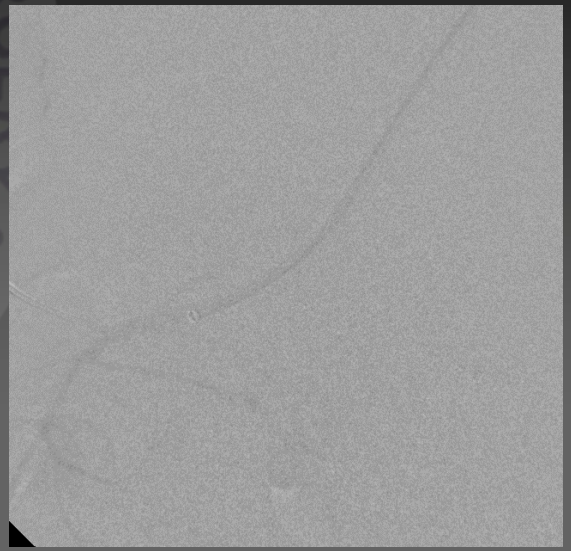

Case 2

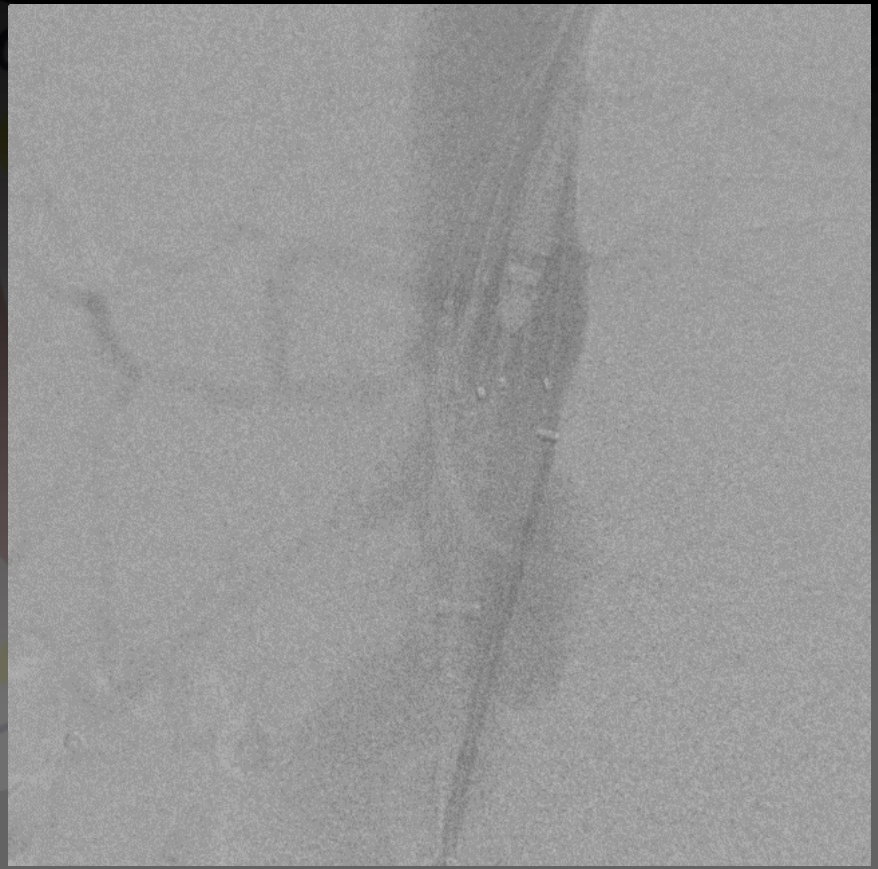

Case 2

Case 2

Case 2

- Transferred to the wards
- Uneventful recovery
- Post-op CTA: ok, no endoleak
- Discharged home 4th post-op day
- 2 years later he is living a normal life

Case 2

1 year later

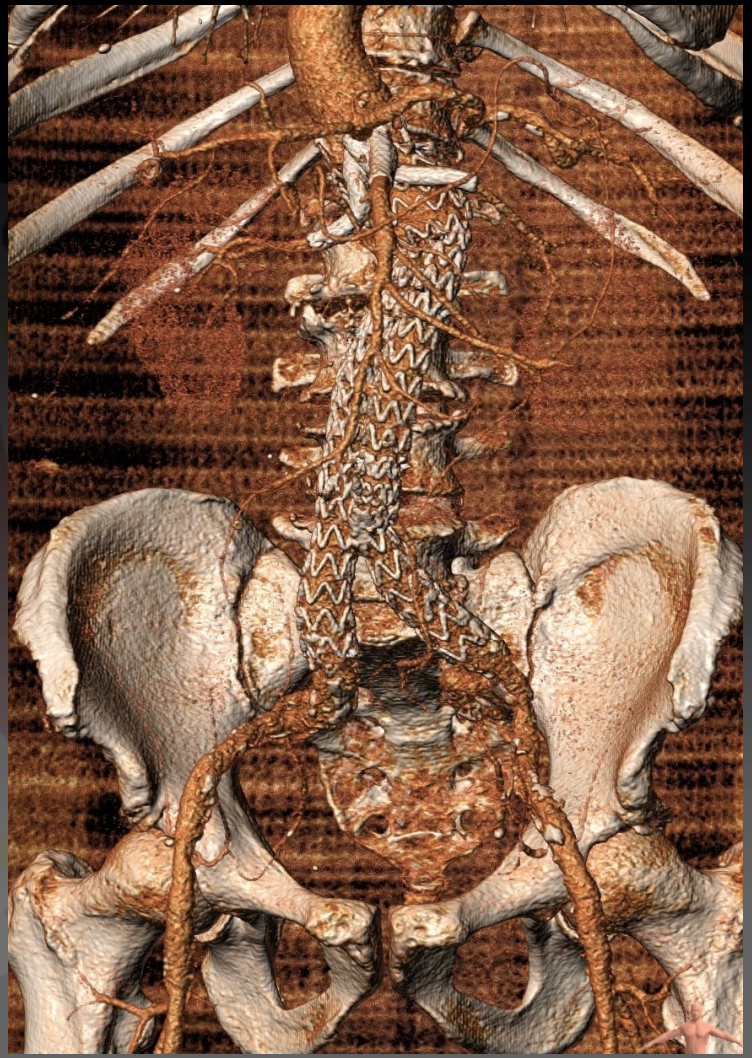

Case 2

1 year later

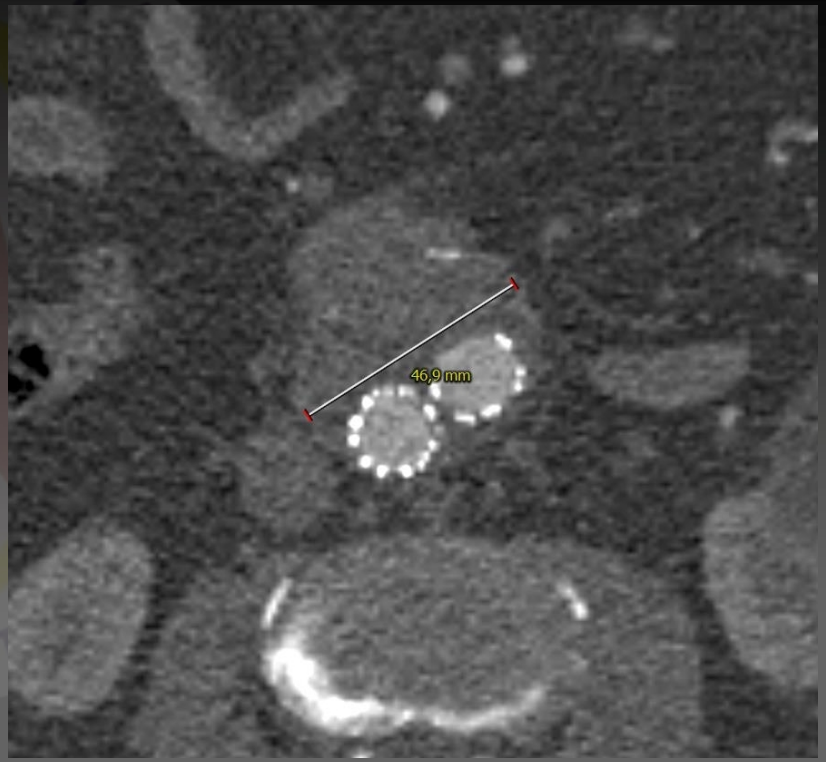

Endovascular treatment of ruptured pararenal abdominal aortic aneurysm using the Chimney technique

George Kouvelos[1], Konstantinos Spanos[1], Petroula Nana[1], Konstantinos Mpatzalexis[1], Nikolaos Rousas1, Metaxia Mpareka[2], Elena Arnaoutoglou[2], Athanasios Giannoukas[1], Miltiadis Matsagkas[1]

[1]Vascular Surgery Department, University Hospital of Larissa, Faculty of Medicine, School of Health Sciences, University of Thessaly, Larissa, Greece
[2]Department of Anesthesiology, University Hospital of Larissa, Faculty of Medicine, School of Health Sciences, University of Thessaly, Larissa, Greece

www.heljves.com
Free access!

Conclusion

- ✓ Anatomical limits are nowadays rarely play a role in endovascular treatment of ruptured AAAs with complex anatomy, given there are adequate endovascular resources namely: **experience, imaging, logistics**
- ✓ The only real limit remains **patient's instability** at admission

Conclusion

- ✓ Given the patient's **stability**, the existence of **adequate endovascular resources** and the needed **experience** in elective cases,
- ✓ **Ch-EVAR** is a **valuable tool** for treating patients with **pararenal ruptured AAA** in terms of:
  - **Availability**
  - **Time**
  - **Cost**

Thank you for your attention!!