



May-Thurner Syndrome (MTS) Patients Presenting with Multisystemic Symptoms that Improve or Resolve after Iliac Venous Interventions:

A Single-Center Experience and
Analysis of Patient and Outcomes

Kurtis Kim, MD FACS, RPVI

Founder

International Foundation of Abdominal Vascular Compression Syndromes



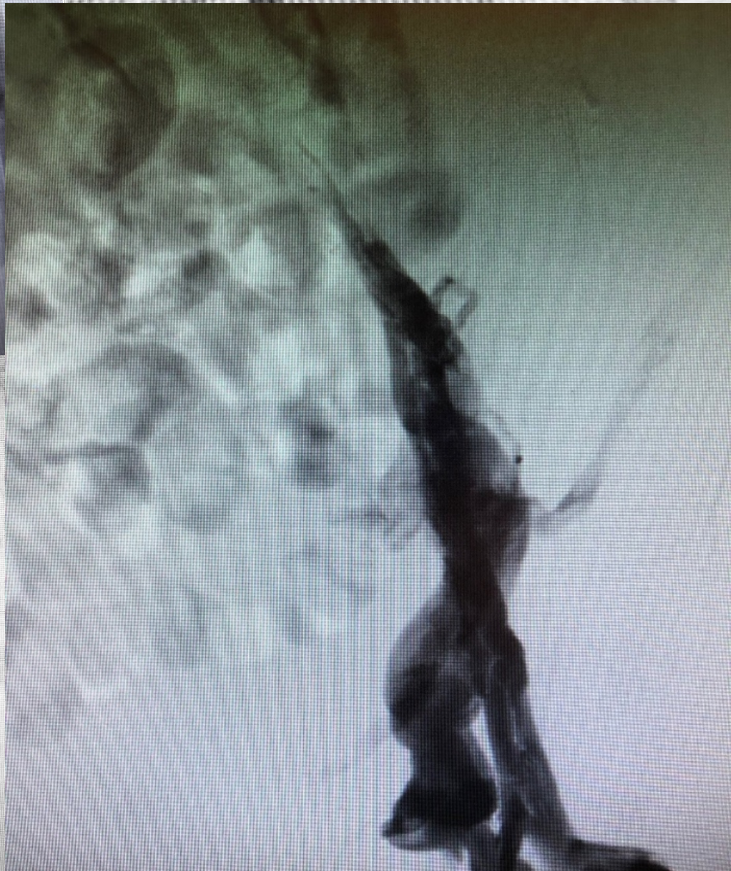
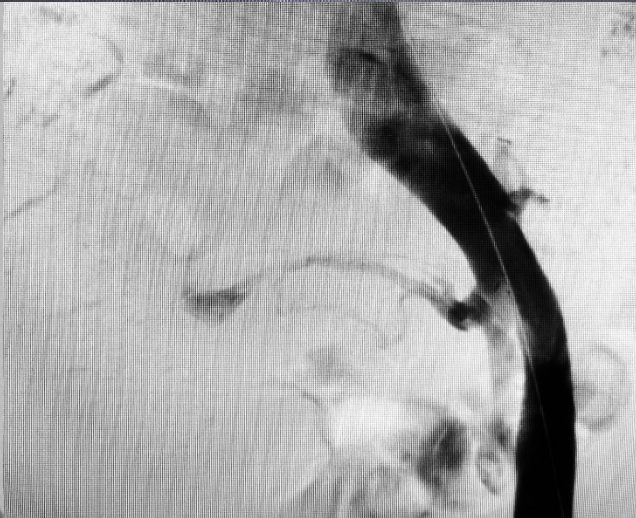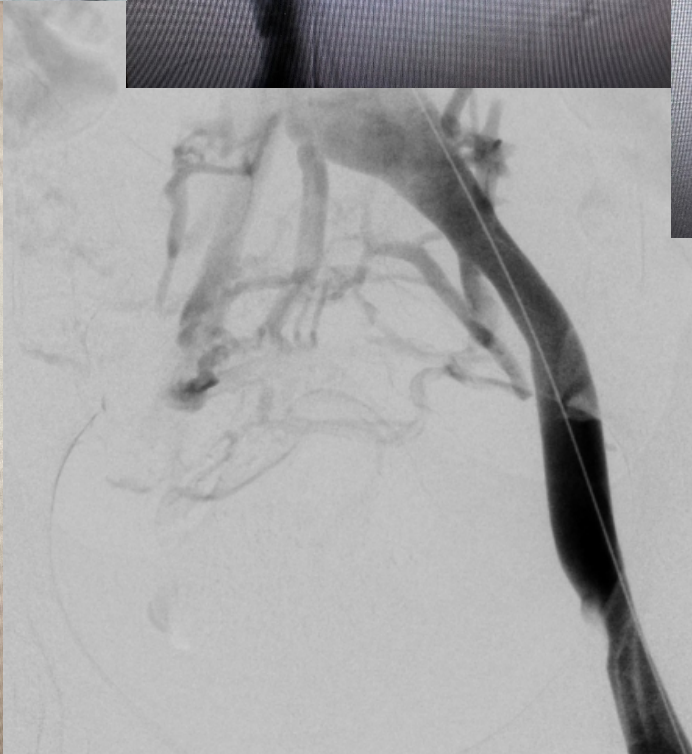
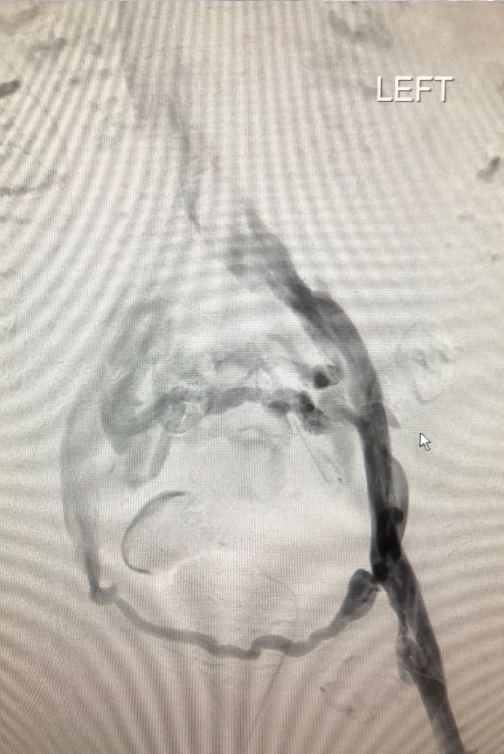
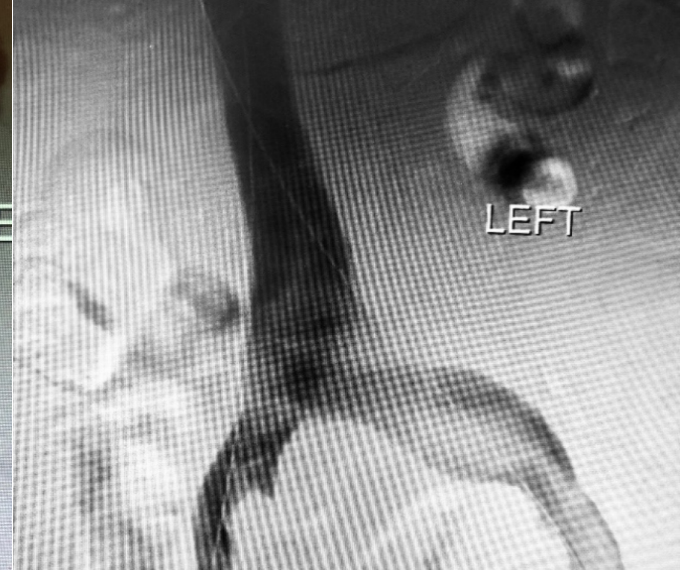
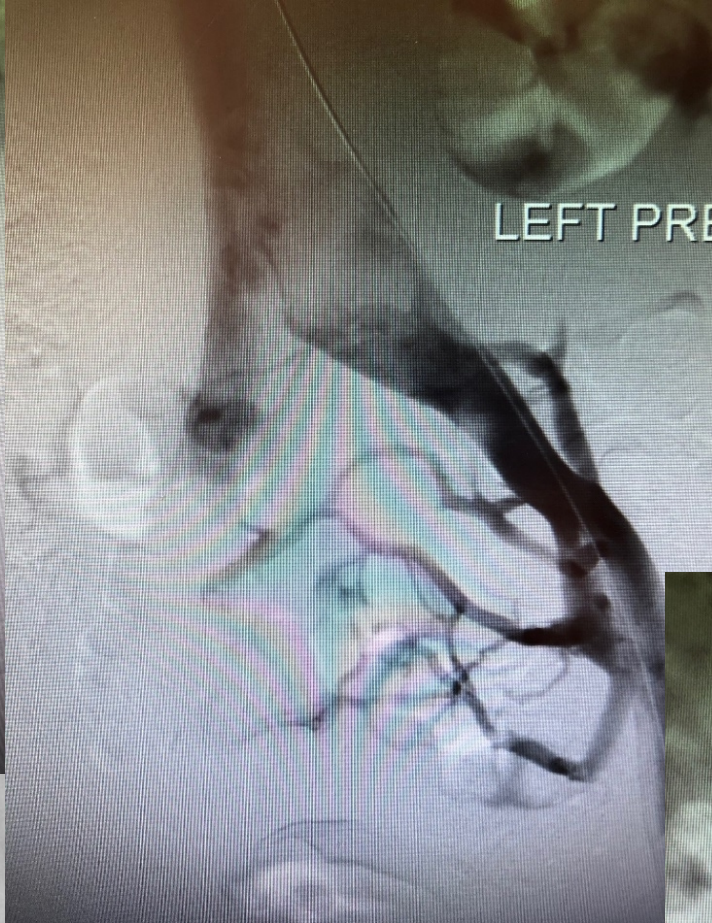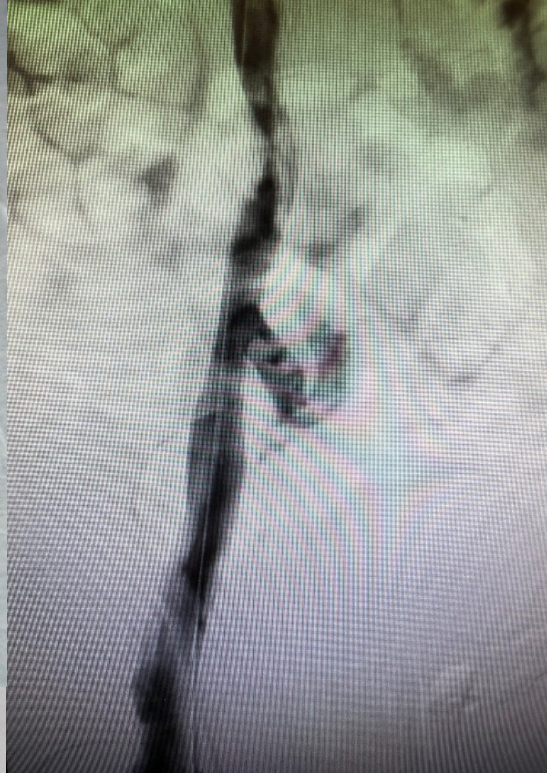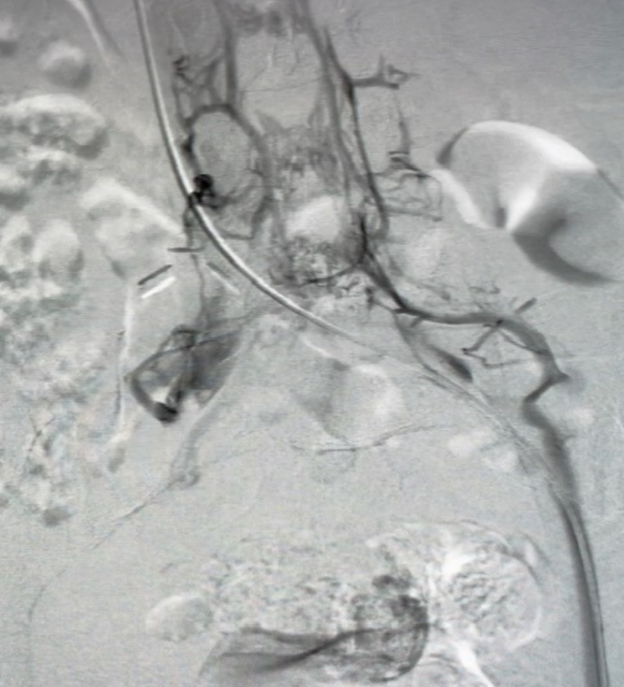
DISCLOSURES:

Research Grants:

W. L Gore, Associates
Tactile Medical
Acelity

Consultant:

Cook Medical





Learning Objectives

- MTS causes more than leg swelling
- 278 out of 576 patient analysis of Non-Thrombotic MTS and their presenting symptoms
- Resolution of various systemic symptoms
- Several Vascular compression Syndromes that Co-Exist in Select Patients:
- “**A**bdominal **V**ascular **C**ompression **S**ndrome:” **AVCS**
 - May Thurner Syndrome
 - Nutcracker Syndrome
 - Median Arcuate Ligament Syndrome
 - Superior Mesenteric Artery Syndrome
 - Pelvic Congestion Syndrome (Pelvic Venous Insufficiency)



70th ESCVS
International Congress of the European Society
for Endovascular and Interventional Surgery

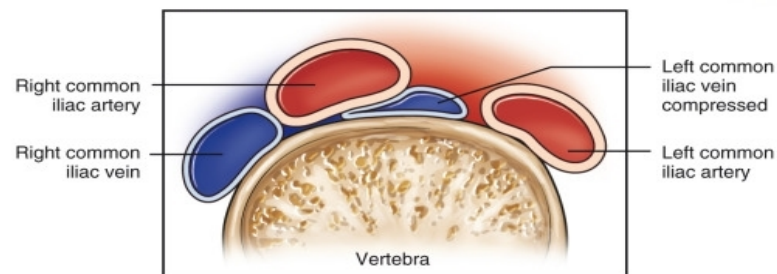
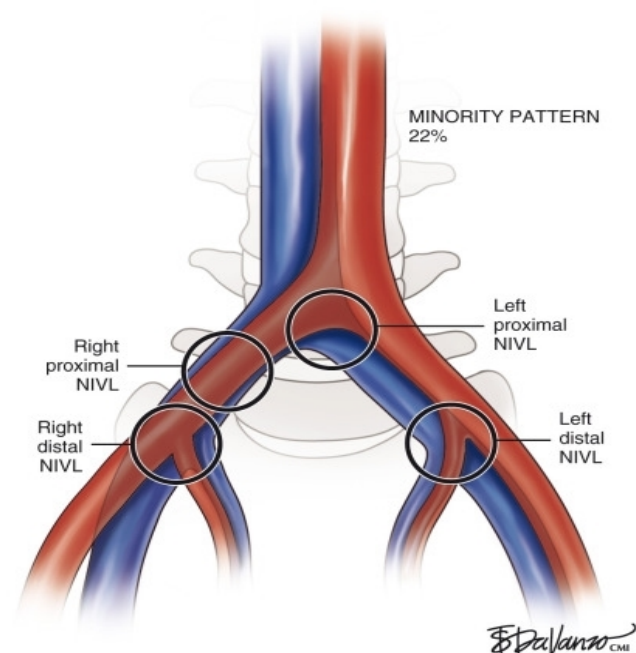
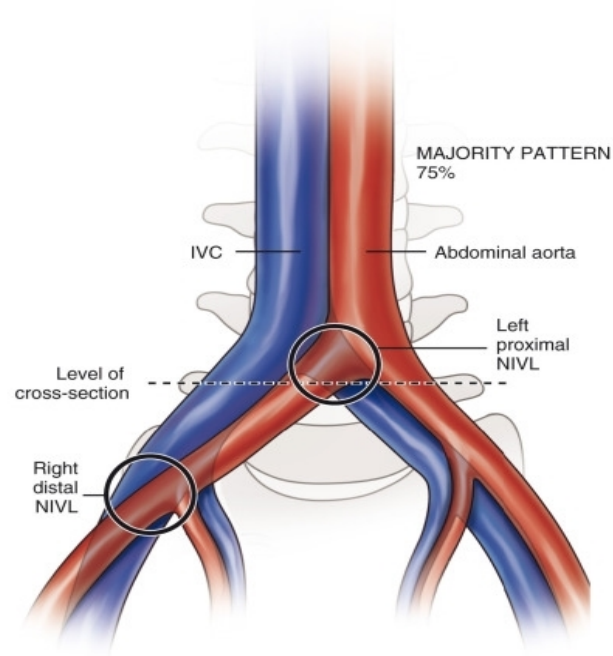


7th IMAD meeting
International Meeting of Arterial and Venous
Disease

20 | 23 JUNE 2022

Liège | Théâtre de Liège | Belgium
www.escvs2022.com

Iliac Venous Compression Anatomy





Multisystemic Presentation: 22 YO Female

Dizziness, palpitation on standing,
Frequent Fainting

Cardiac Work Up Negative

Constipation, Bowel Pain & Cramps

GI Work Up: Irritable Bowel Disease

Pelvic Pain, Bloating

GYN Work Up Negative for known Dz

Back Pain

Ortho Work Up Negative for known Dz

Frequent UTI & Symptoms

Urology Work Up Negative for known Dz

Always Tired, and No Energy

Medical Work Up: Chronic Fatigue Syndrome

Leg: Mild swelling, heaviness

Vascular Work Up: MTS

Delayed
Venous Return

Extensive
Paravertebral
Venous HTN


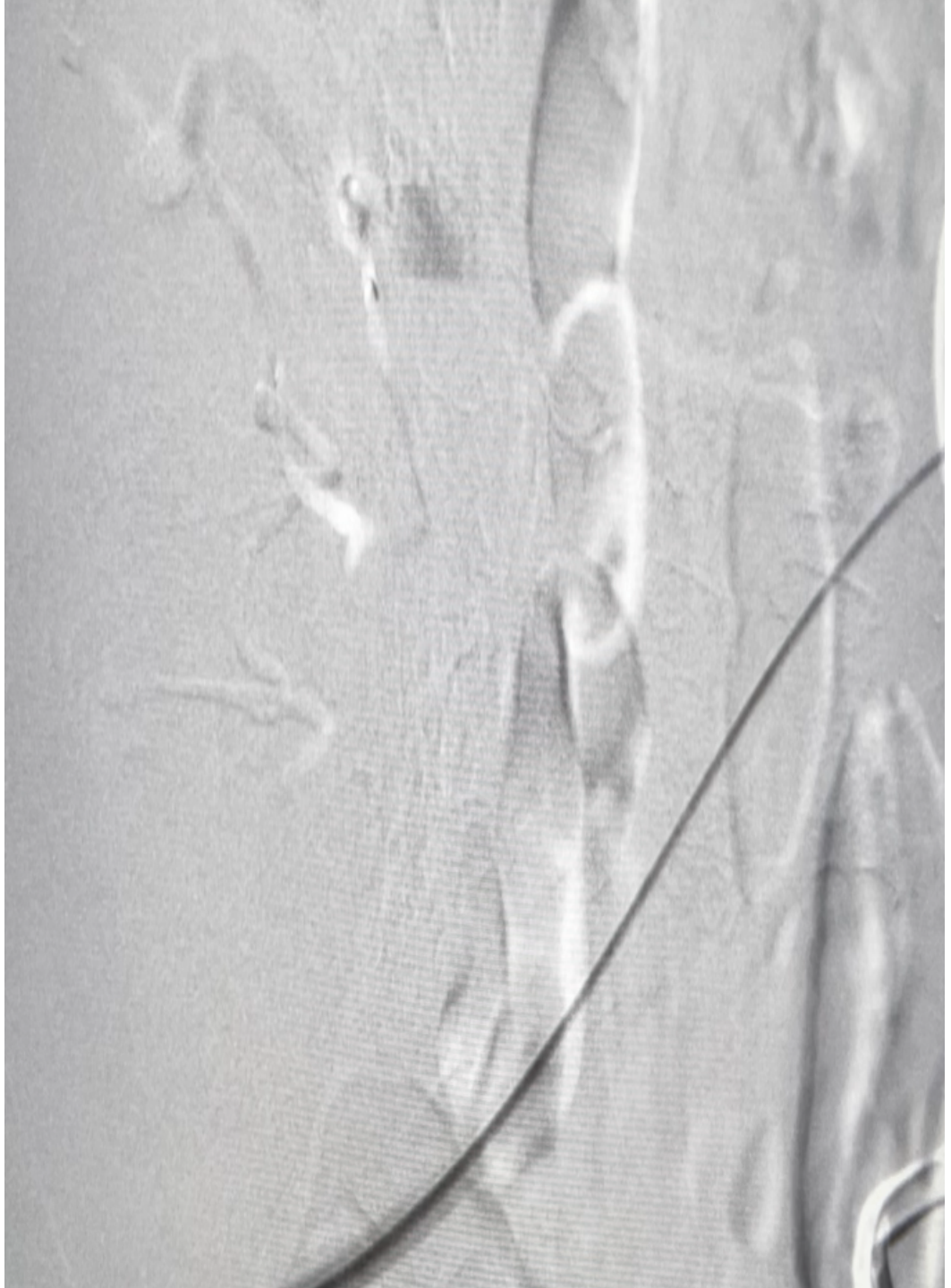


 **70th ESCVS**
European Society for
Cardiovascular and Endovascular Surgery

 **7th IMAD meeting**

20 | 23 JUNE 2022

Liège | Théâtre de Liège | Belgium
www.escvs2022.com





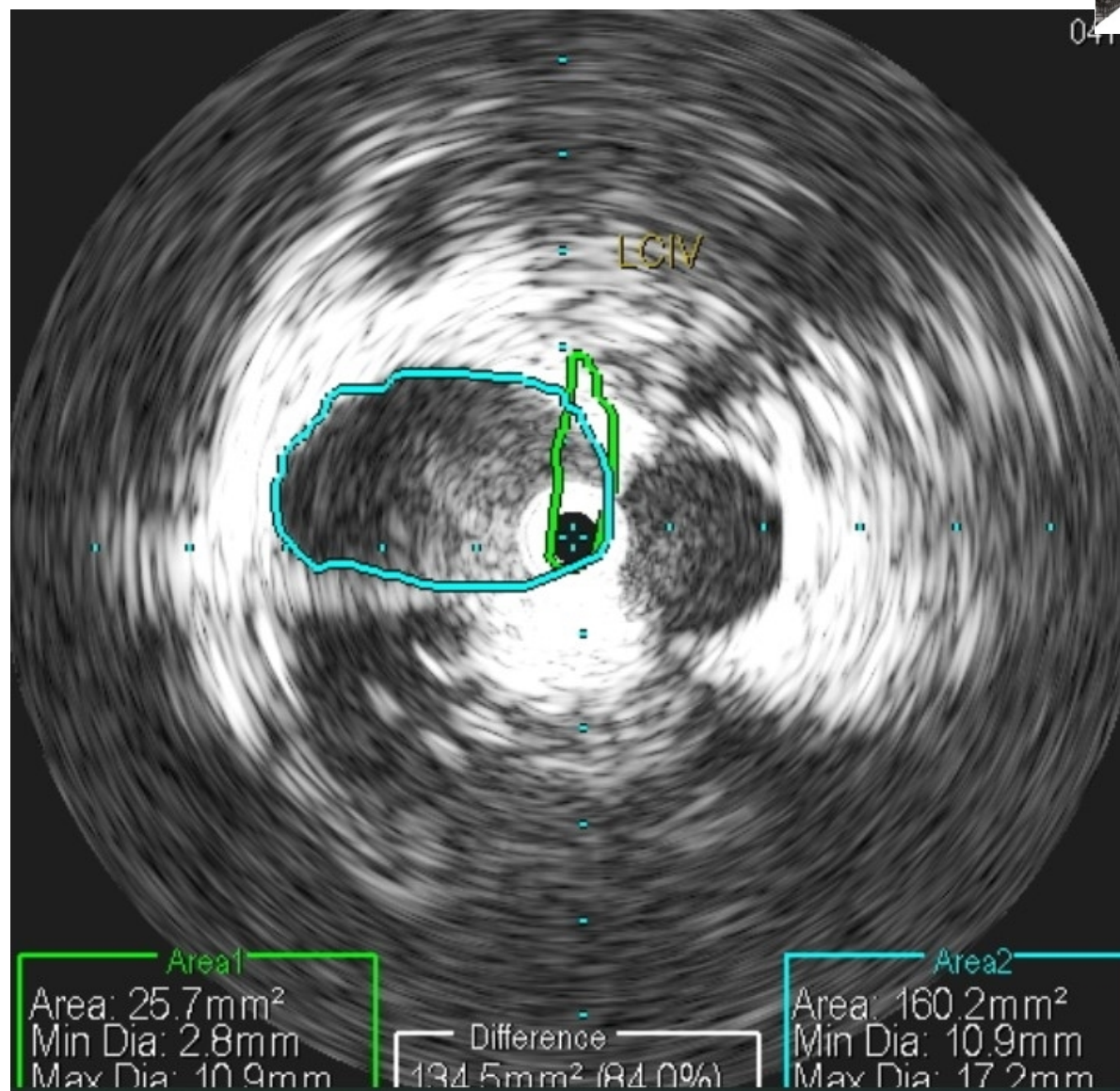
70th ESCVS
International Congress of the European Society
for Cardiothoracic and Endovascular Surgery



7th IMAD meeting
International Meeting for Arterial and Venous Diseases

20 | 23 JUNE 2022

Liège | Théâtre de Liège | Belgium
www.escvs2022.com



84% L CIV
Compression



70th ESCVS
International Congress of the European Society
for Cardiovascular and Endovascular Surgery



7th IMAD meeting

20 | 23 JUNE 2022

Liège | Théâtre de Liège | Belgium
www.escvs2022.com

LEFT

Post Stent from
distal IVC to distal
LCIV

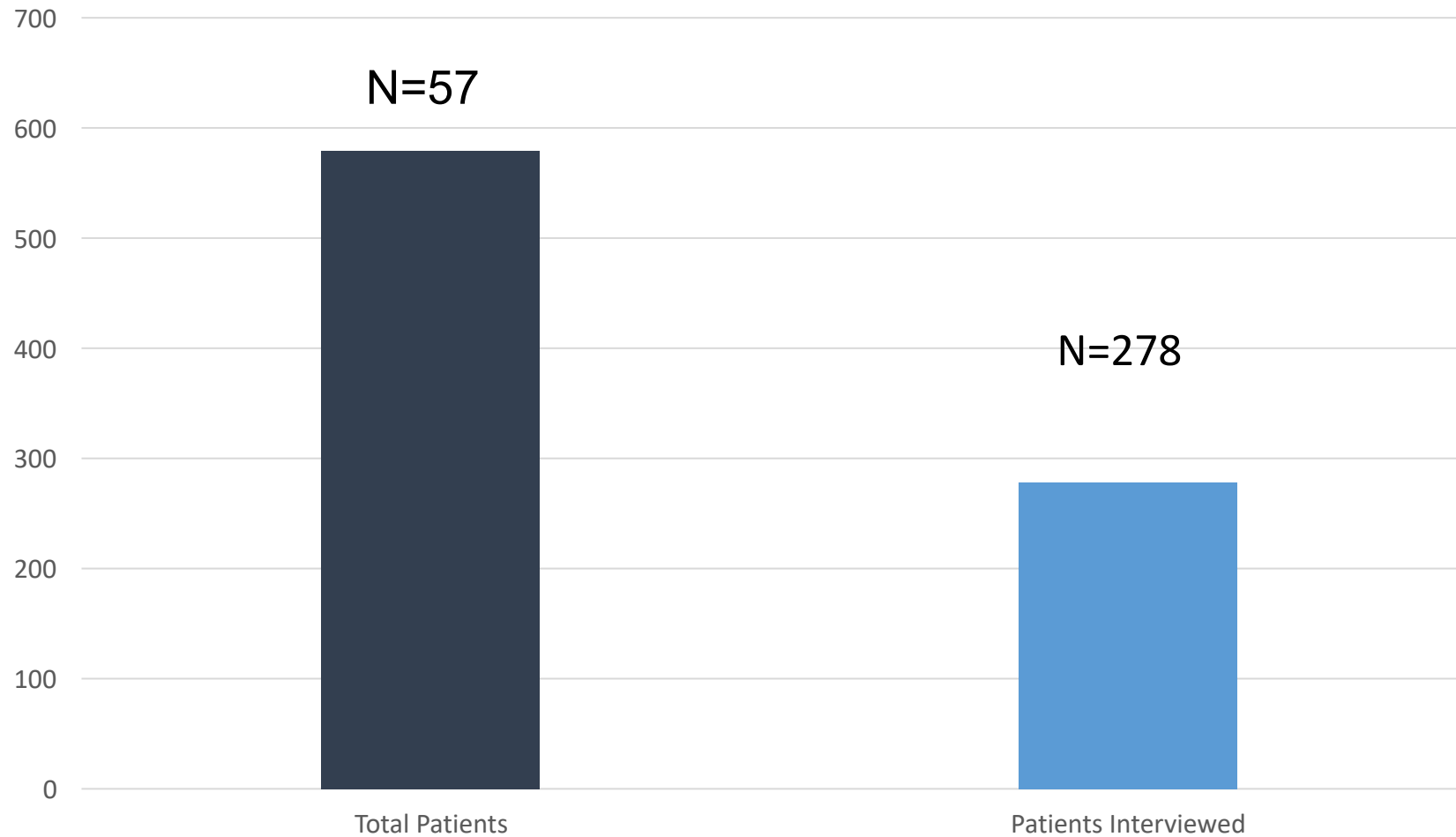


Methods

- Patients were either called or interviewed on their follow ups: 3-60 months
- All are **Non-Thrombotic MTS Patients**
- Detailed questions regarding multisystemic symptoms were asked:
 - Cardiovascular
 - Neurological
 - Genitourinary
 - Gynecological
 - Gastrointestinal
 - Orthopedic-Like Symptoms
 - Vascular Symptoms : All had symptoms thus not included in is presentation for the purpose of topic

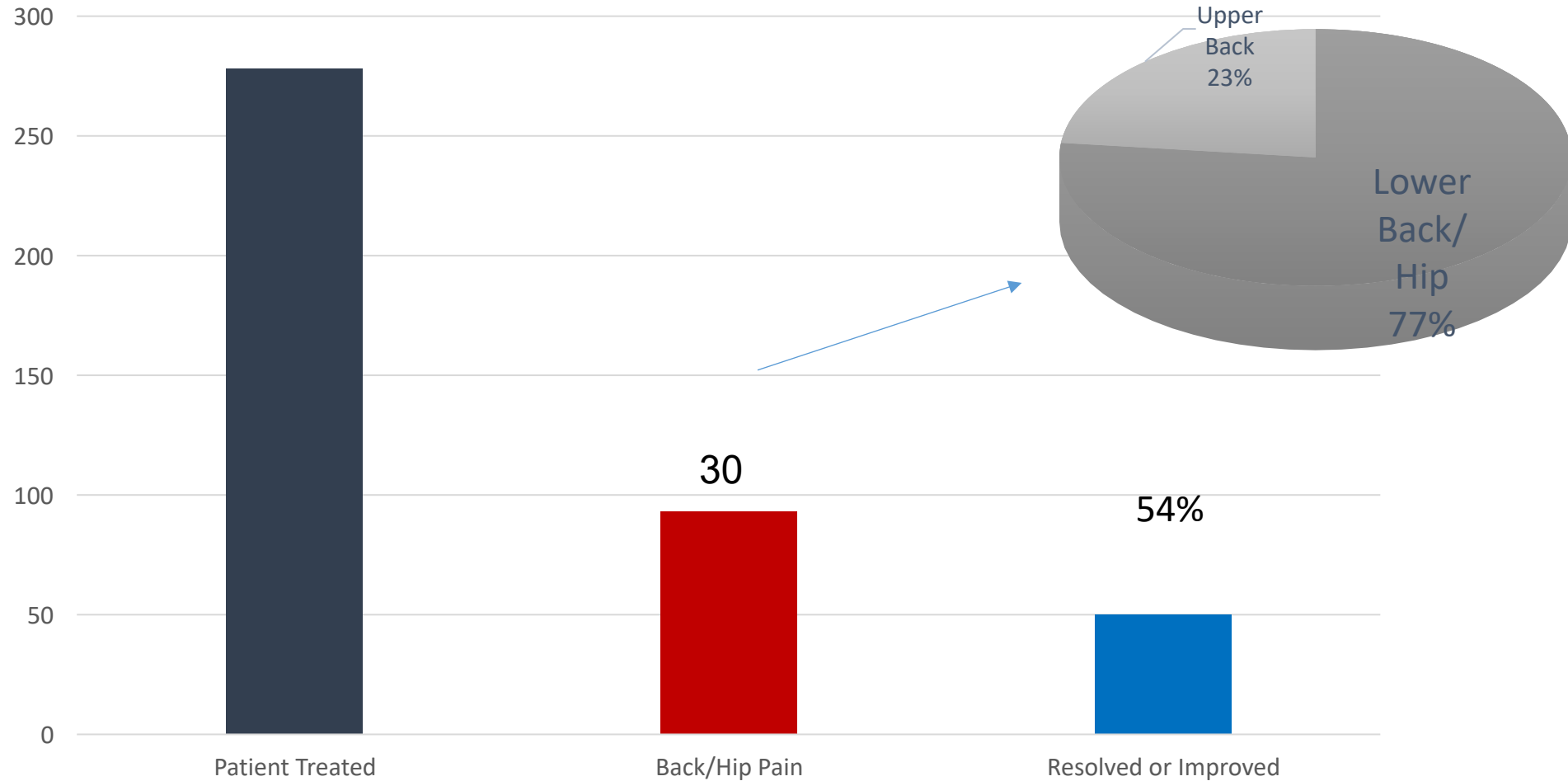


Non-Thrombotic MTS Treated



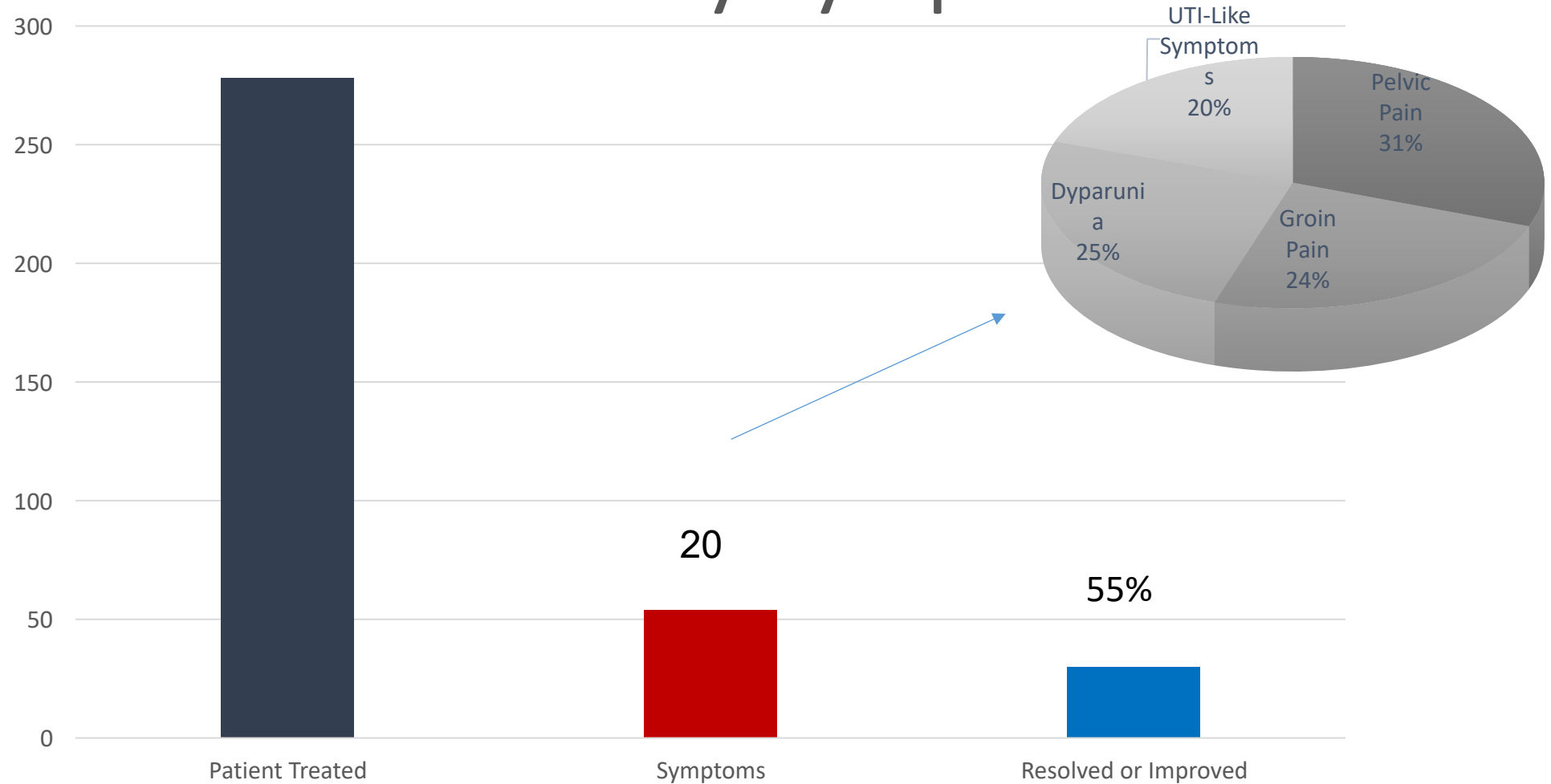


Orthopedic-Like Symptoms



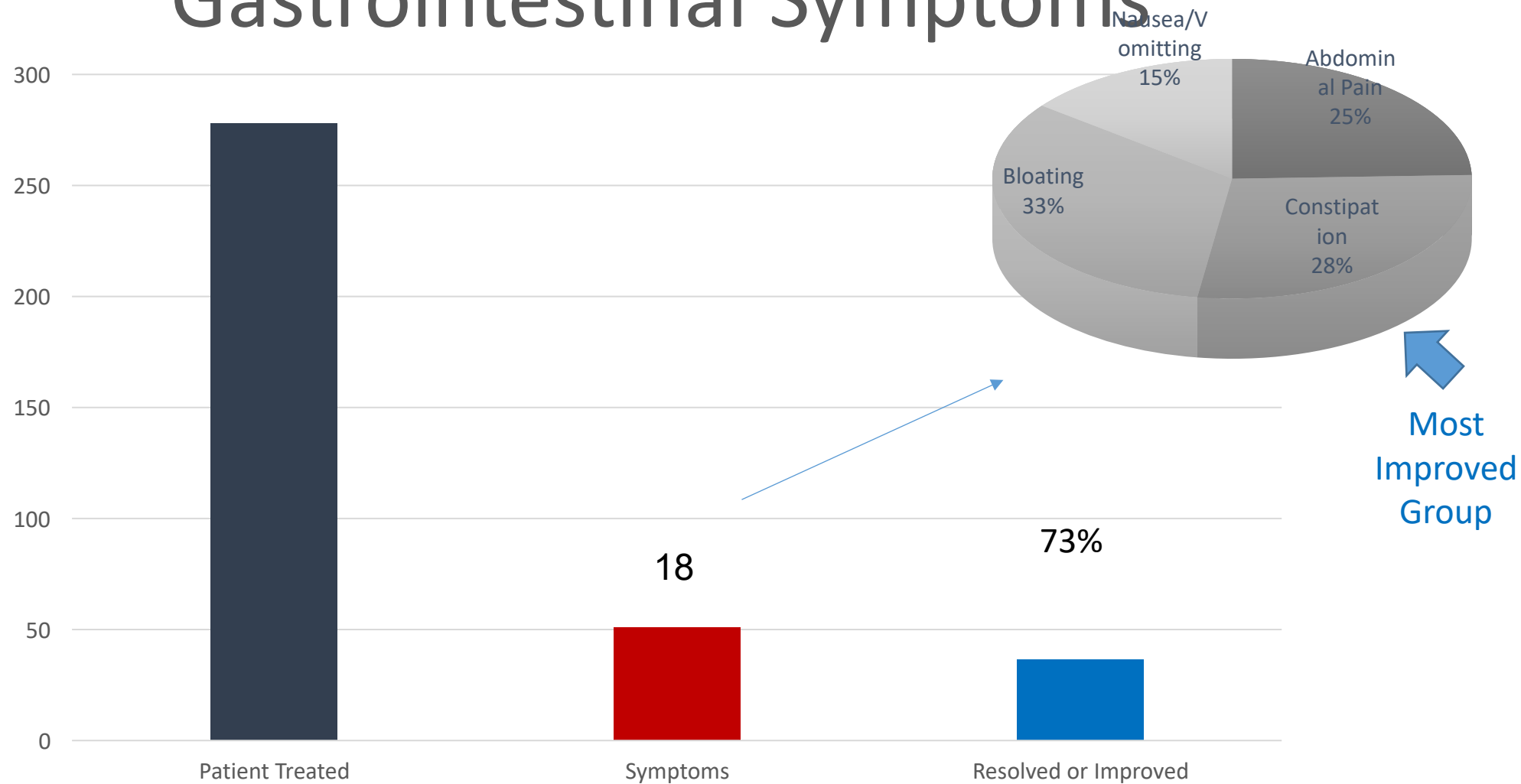


Genito-Urinary Symptoms



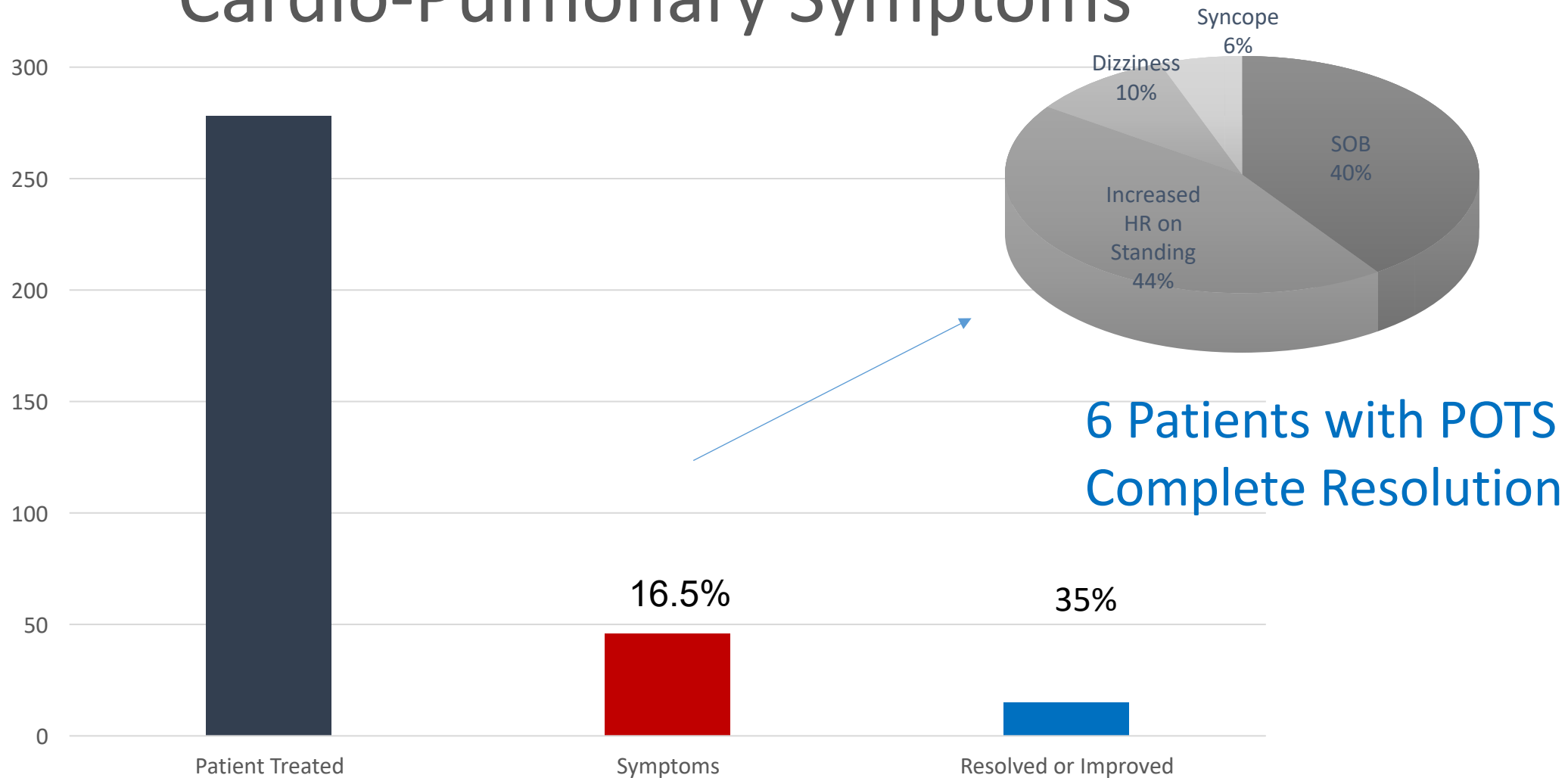


Gastrointestinal Symptoms



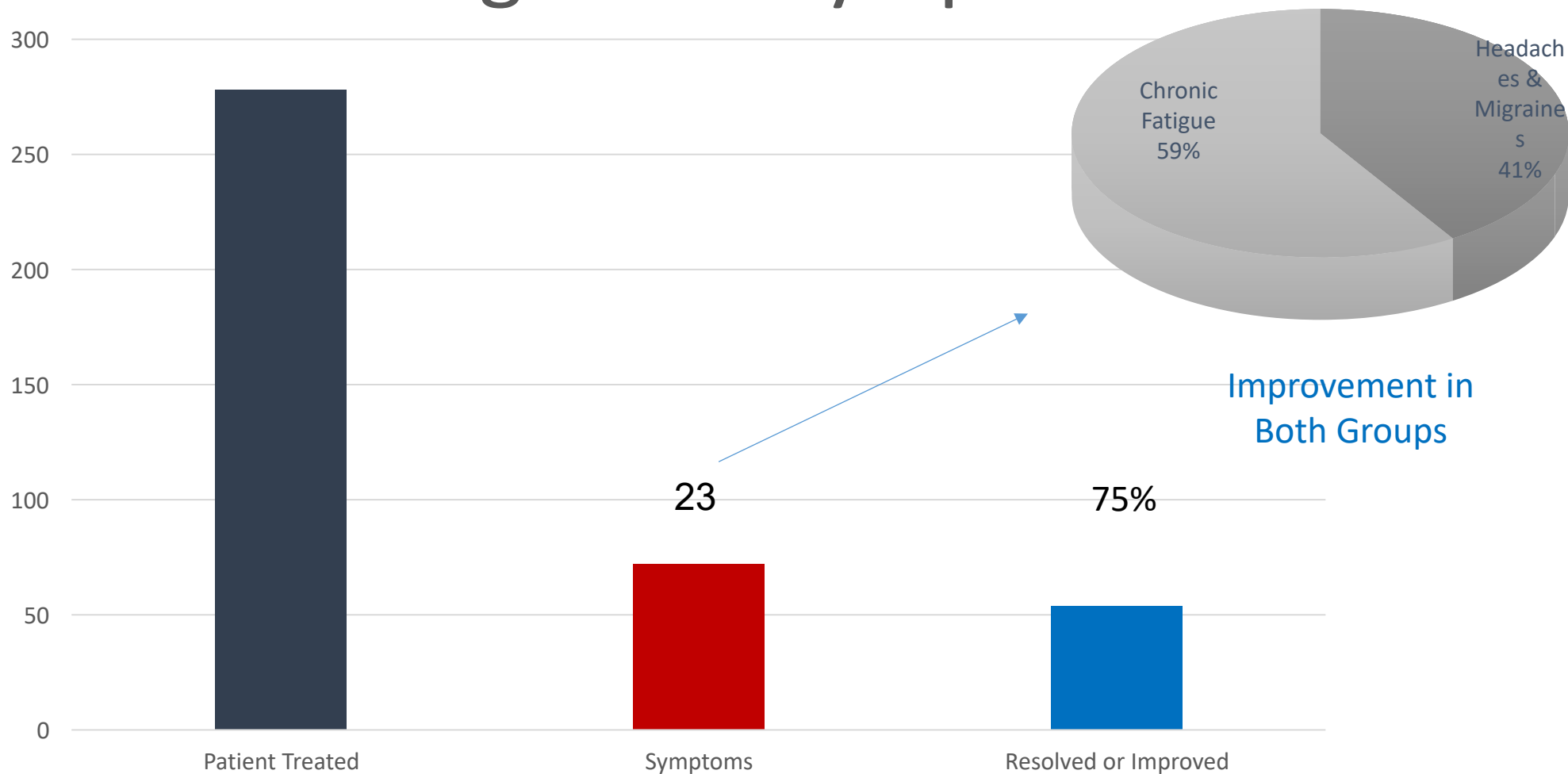


Cardio-Pulmonary Symptoms



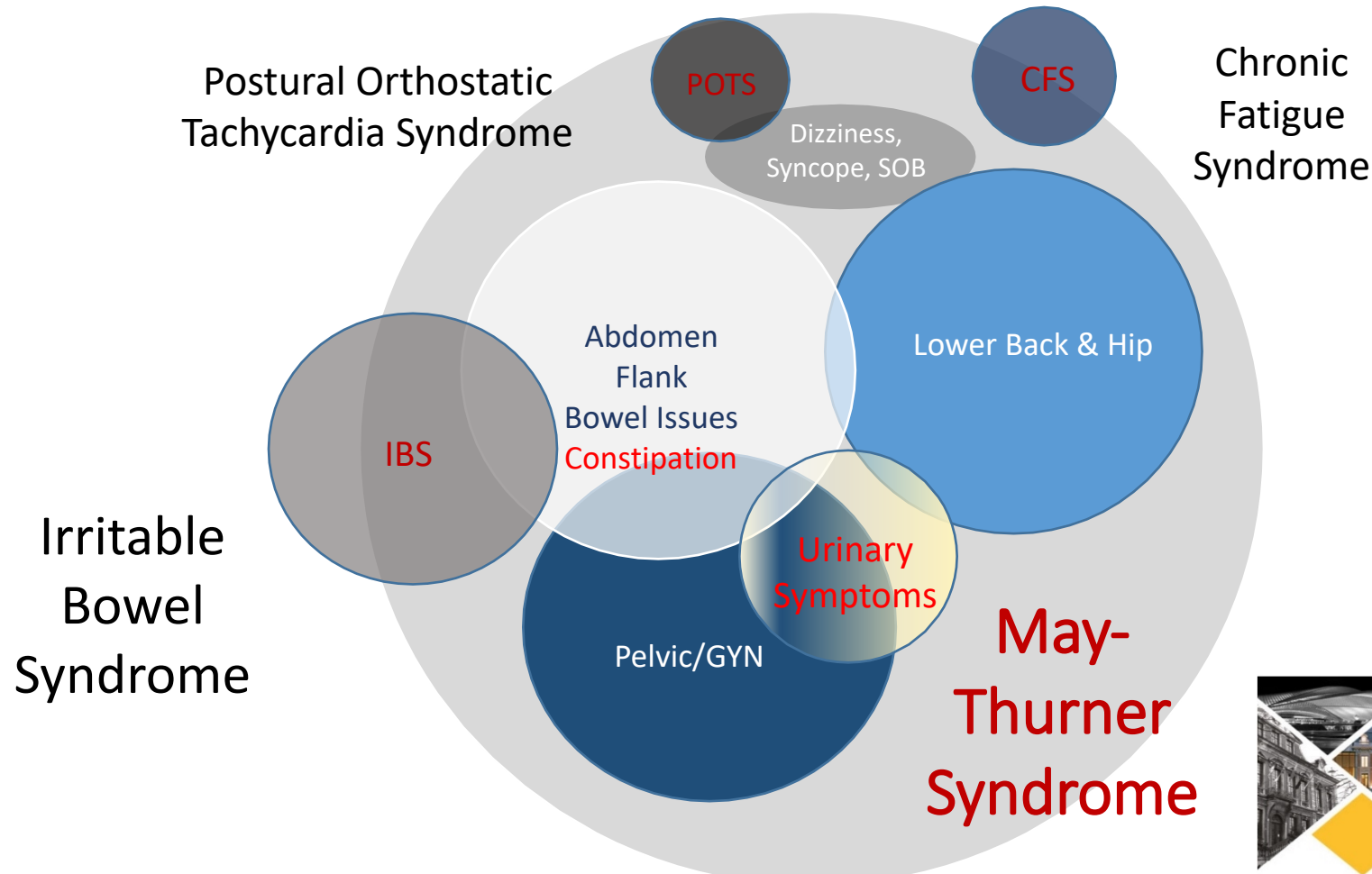


Neurologic-Like Symptoms



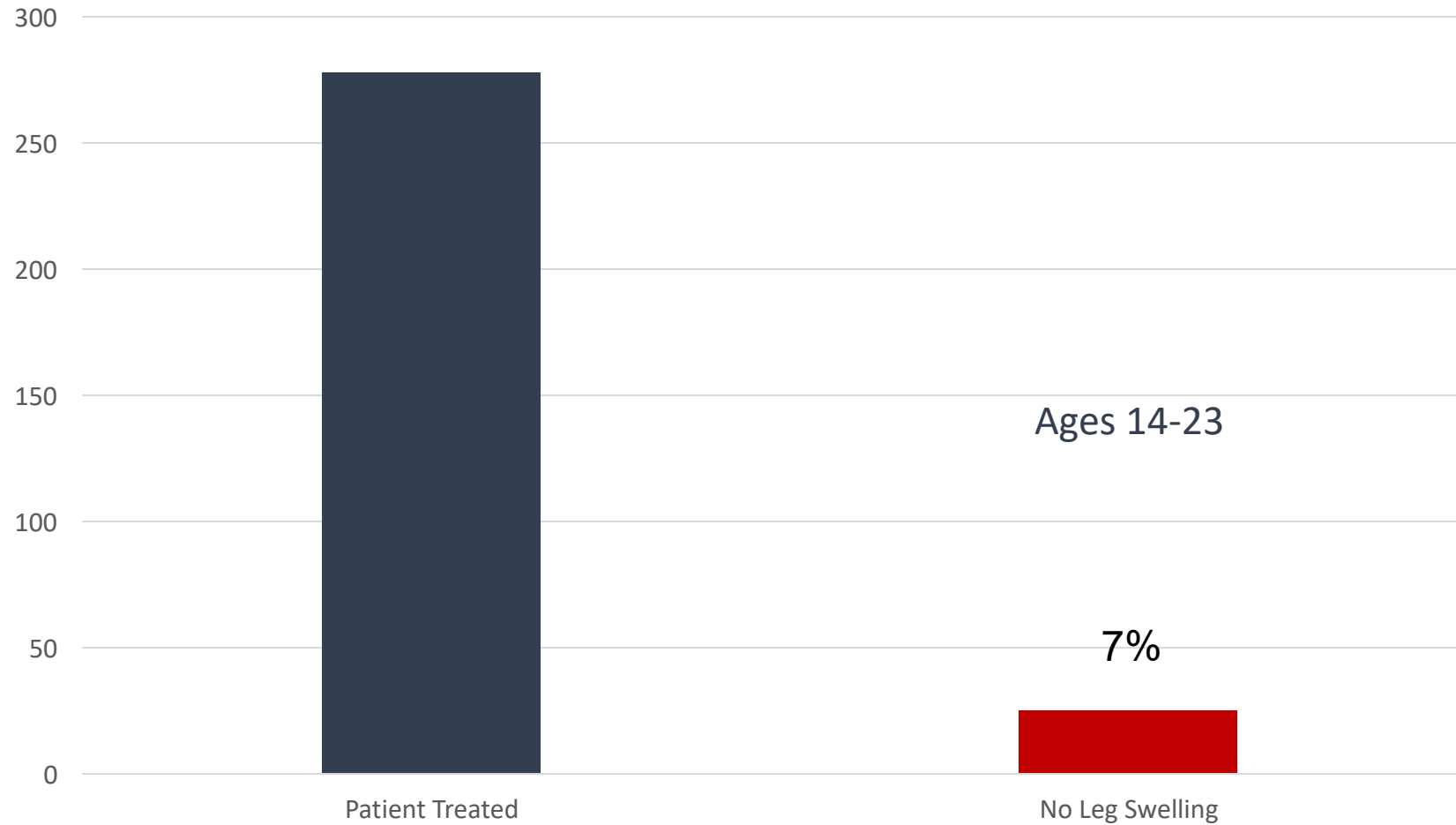
Multisystemic Presentation of Iliac Venous Compression Symptoms

When Lacking Primary Diagnosis

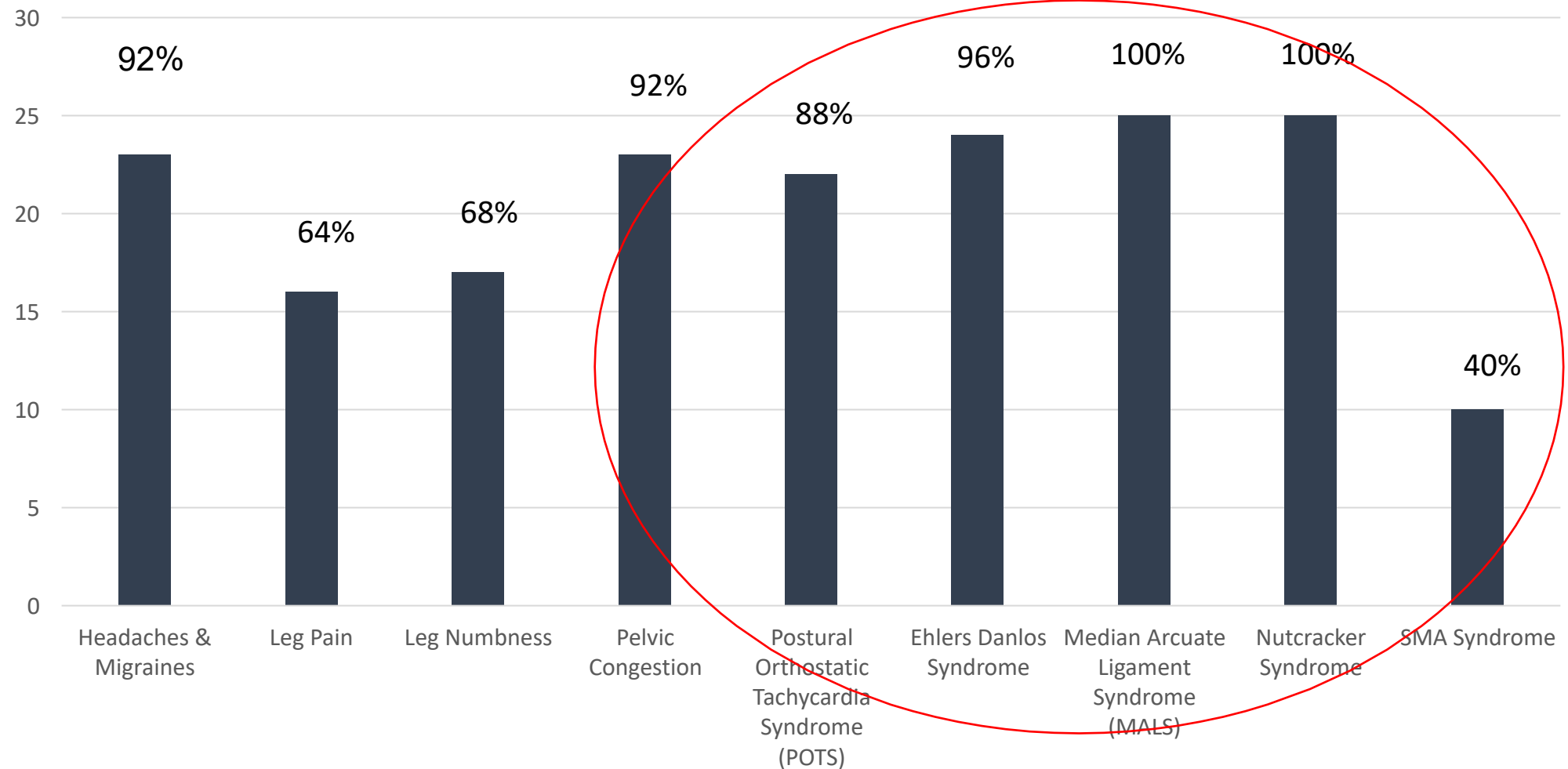




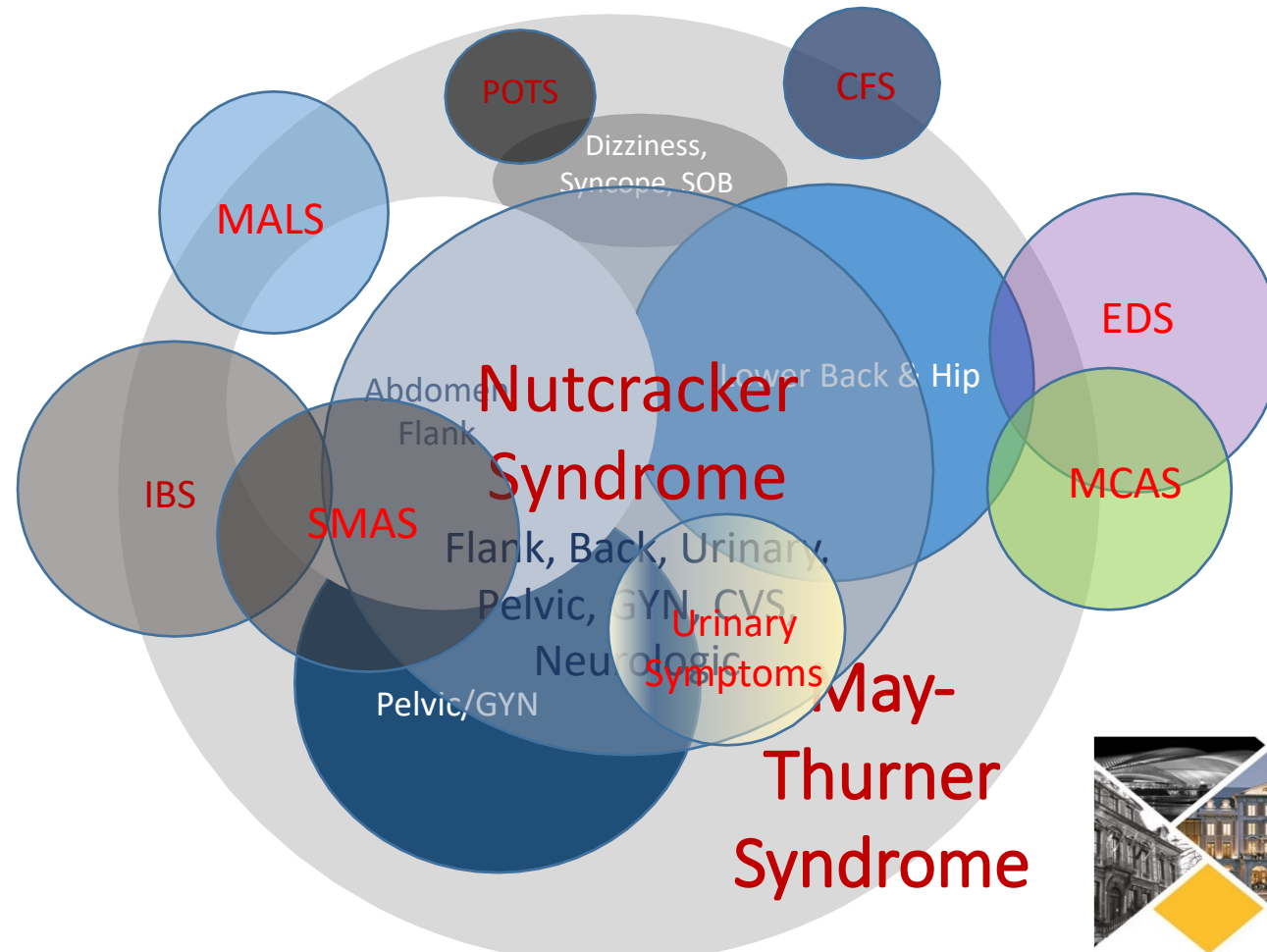
No Leg Swelling



Presenting Symptoms and Diagnosis In Nutcracker Group (Ages 14-32)



Multisystemic Presentation of Venous Compression Symptoms



Summary



- There are more to leg swelling in the Iliac Venous Compression Disease:
May-Thurner Syndrome
- Recognition of multisystemic presentation of MTS
- Patients presenting with multiple **A**bdominal **V**ascular **C**ompression **S**ndrome (**AVCS**) with or without leg swelling, and genetic predisposition in relation to EDS, warrants further investigation