Universitätsmedizin Essen
Universitätsklinikum

Hybrid repair of acute type A aortic dissection with visceral malperfusion

Konstantinos Tsagakis, MD, PhD
Department of Thoracic and Cardiovascular surgery
West German Heart and Vascular Center
University Hospital Essen, Germany

Background

True Lumen (TL) Collapse and Malperfusion in acute Type I Aortic Dissection (AD)

Malperfusion (especially visceral malperfusion)
is the „main killer“ in acute aortic Type I aortic dissection

- GERAADA: 21 - 43%

Czerny et al, Am. Coll. Cardiol. 2015

- Japan - Registry: 17 - 42.8%

Okita et al, Ann Cardiothorac Surg 2016

Persisting Malperfusion after Proximal Ao. Repair = Severe Metabolic Disorder

Case Example 79y/o, visceral malperfusion after prox. repair

Onset of symptom to diagnosis / OR

Proximal aortic repair

Re-evaluation of malperfusion

Malperfusion treatment

>15 hours

Procedure: fenestration after proximal aortic repair
Outcome: death on metabolic disorder and acute cardiac failure

Extended Thoracic Ao. Treatment in Acute Type A AD

Frozen Elephant Trunk Surgery

E-vita open Plus

Thoraflex

E-vita open Neo

Advantage

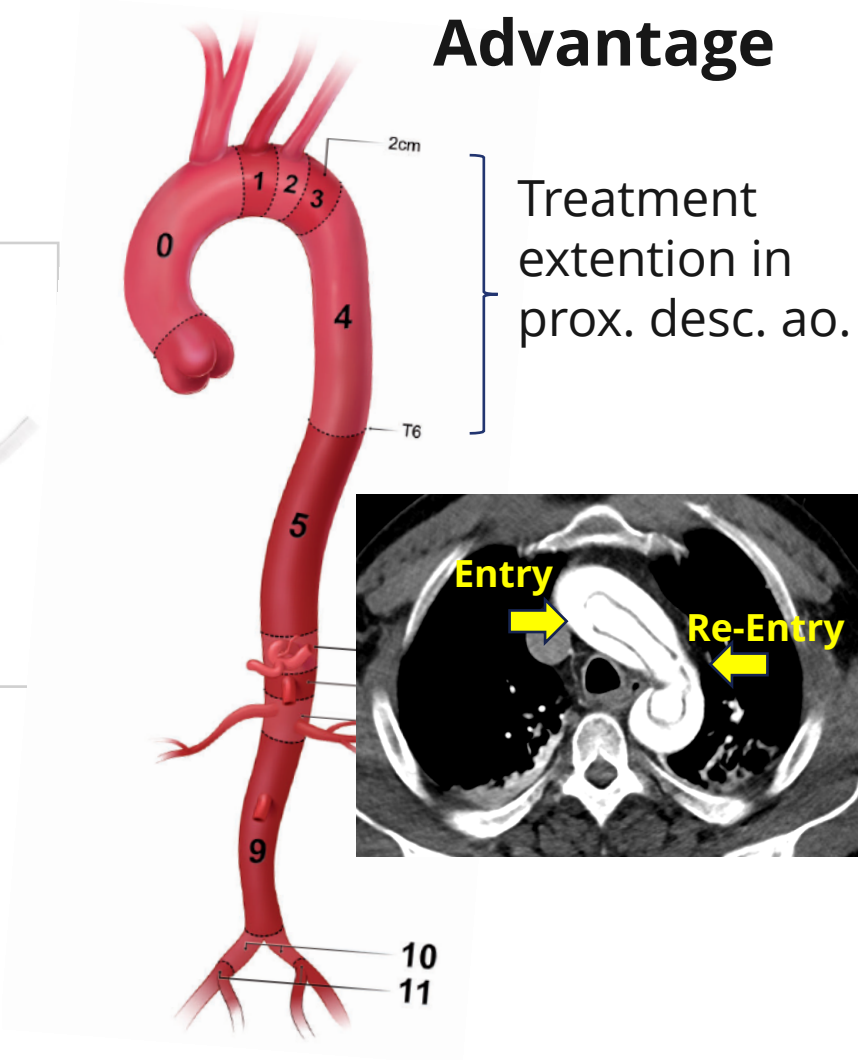

Treatment extention in prox. desc. ao.

Extended Thoracic Ao. Treatment in Acute Type A AD

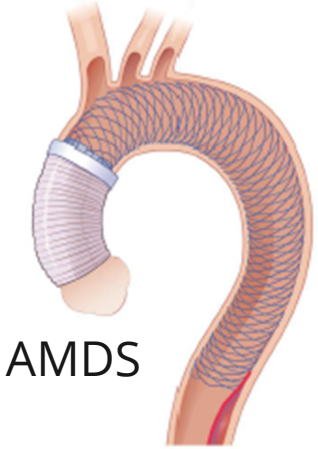

AMDS

Arch+Descedning Ao. Stenting

	Coeliac Trunc	Sup. Mesenteric art.	Iliac artery
Preop.	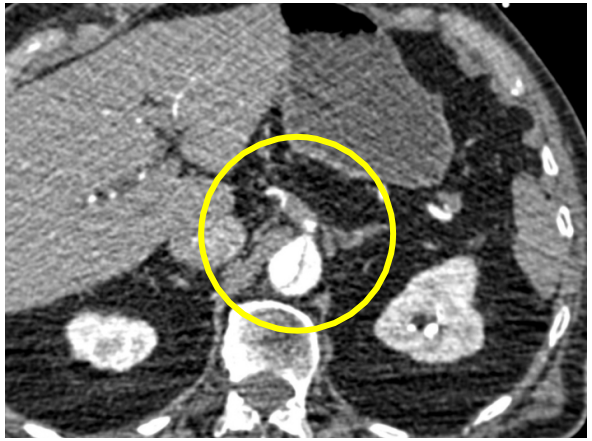	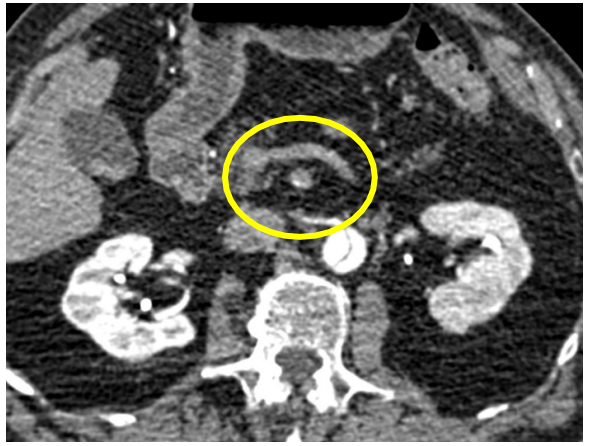	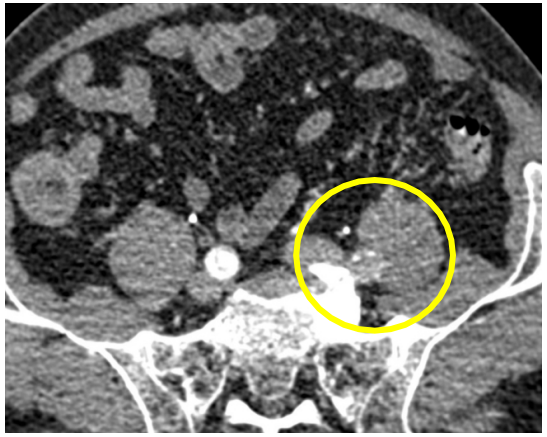
Postop.	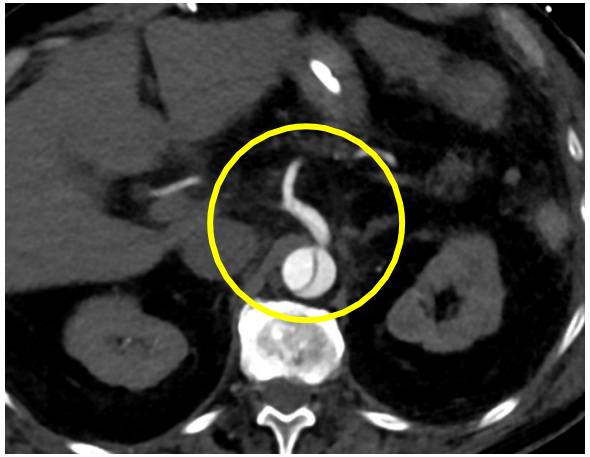	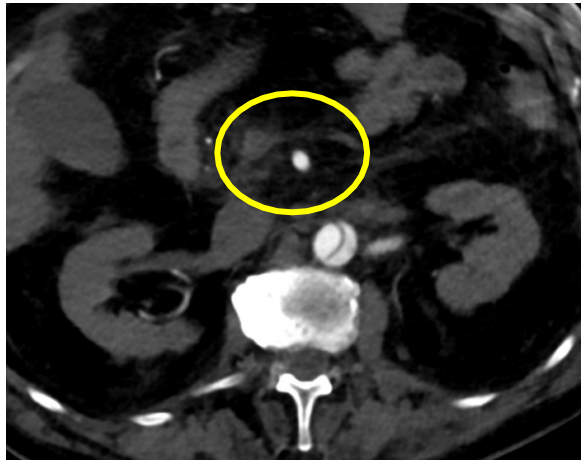	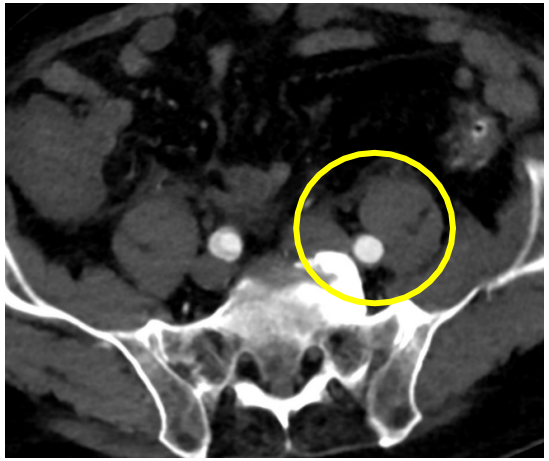

Dynamic Malperfusion - Case Example (FET)

40y, male, marfan, abd. pain, vomiting

Preop. - Complete TL collapse

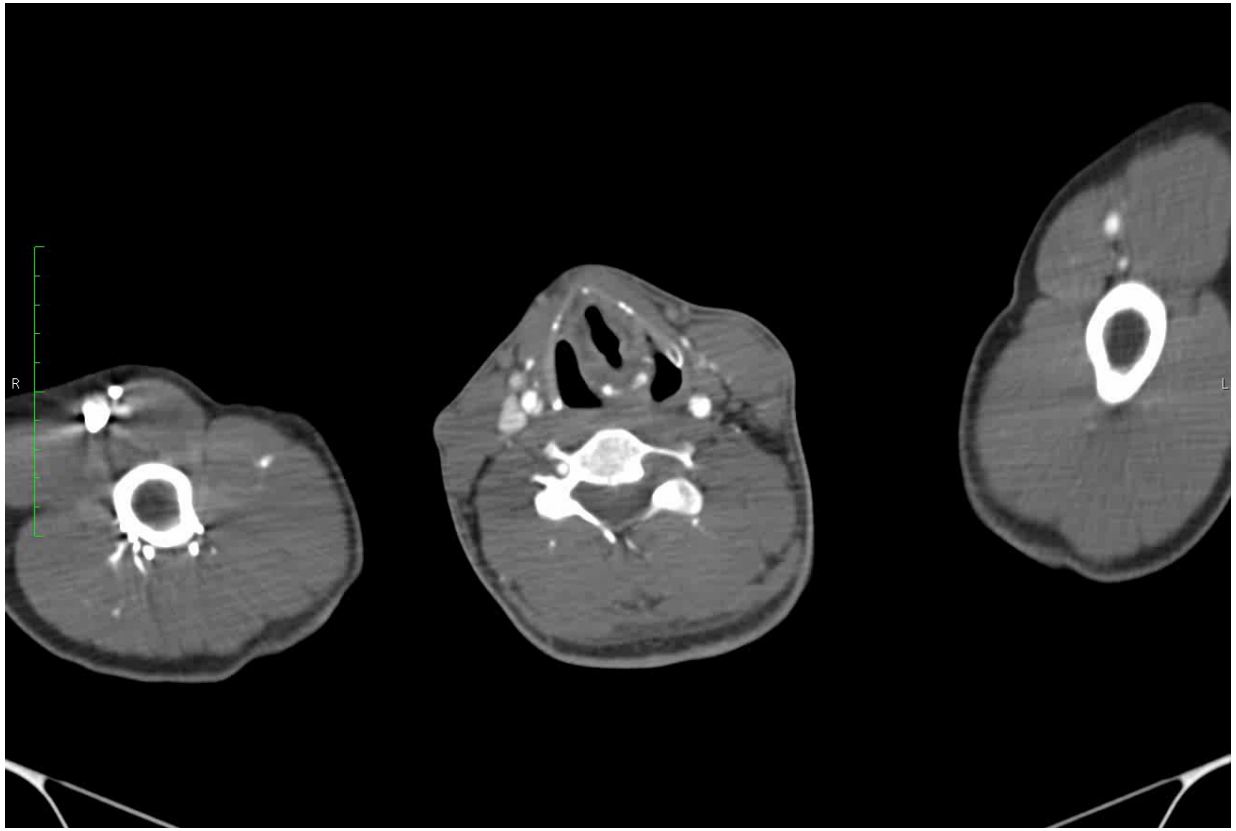

After FET – TL expansion

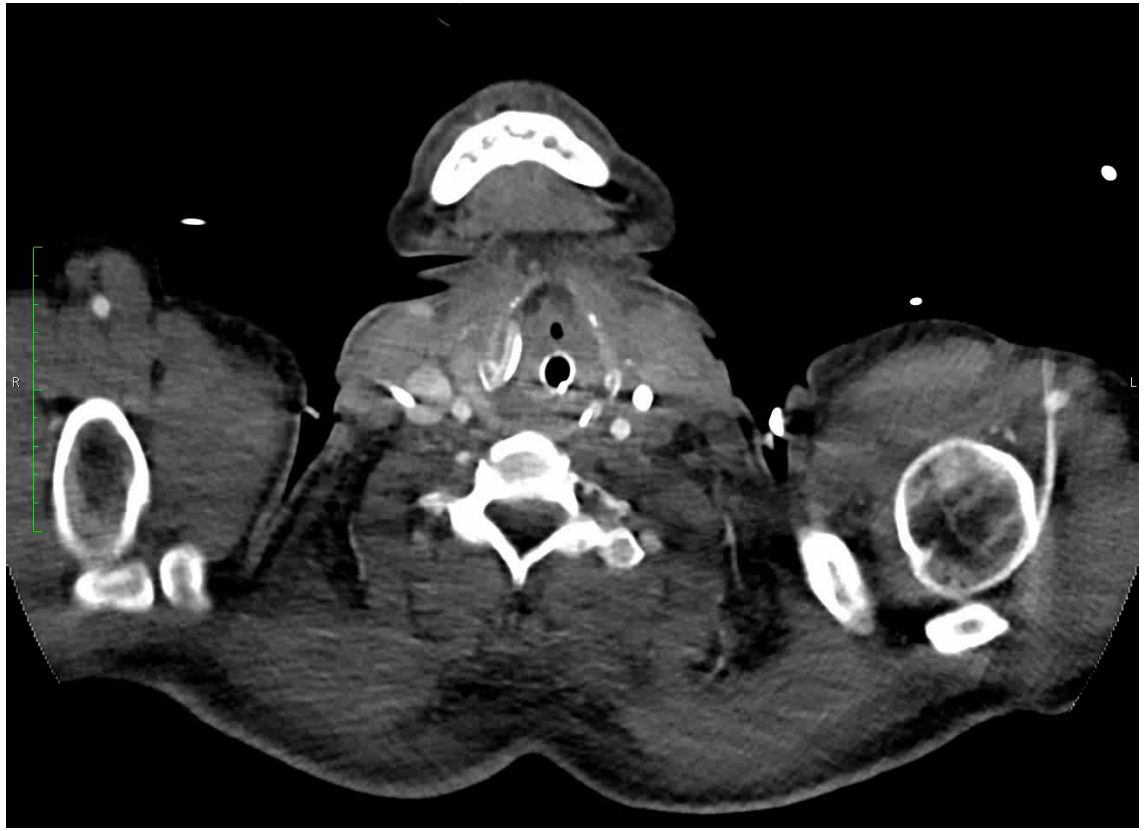

Sustained dynamic Malperfusion after FET

77yrs, female
2nd postop. day after FET - hepatic failure, distended abdomen

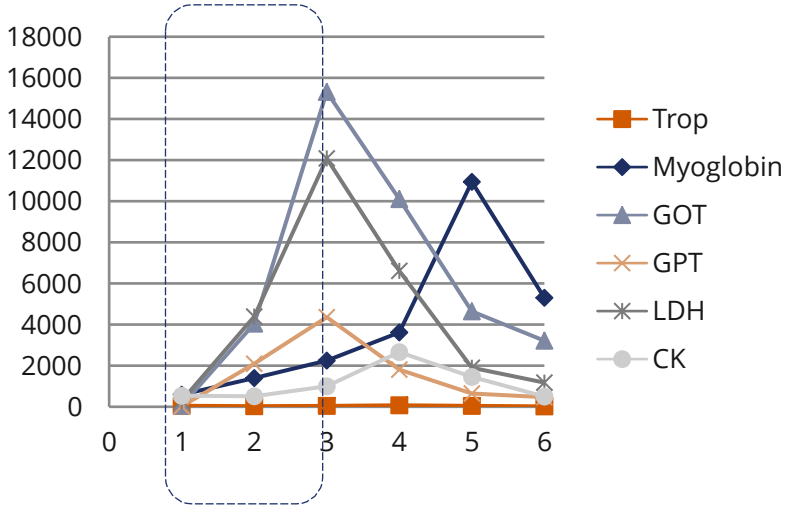

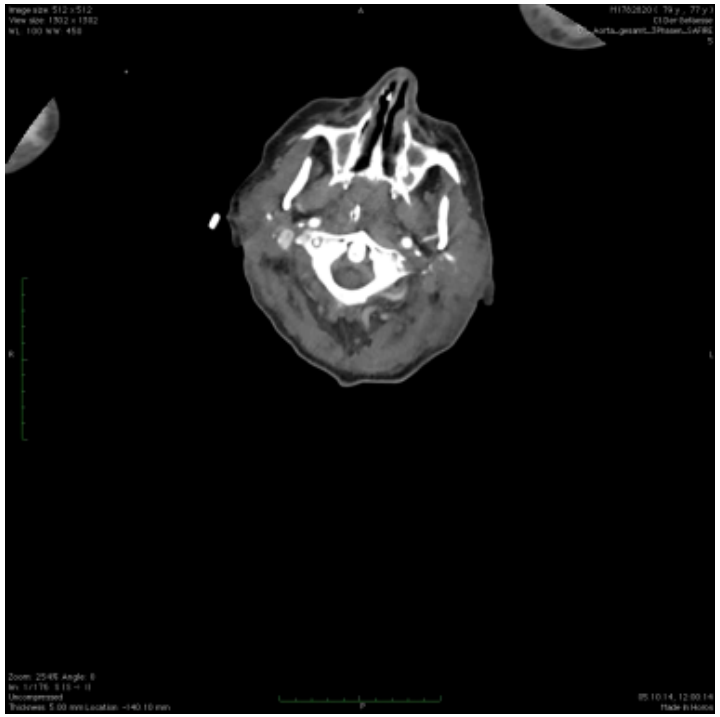

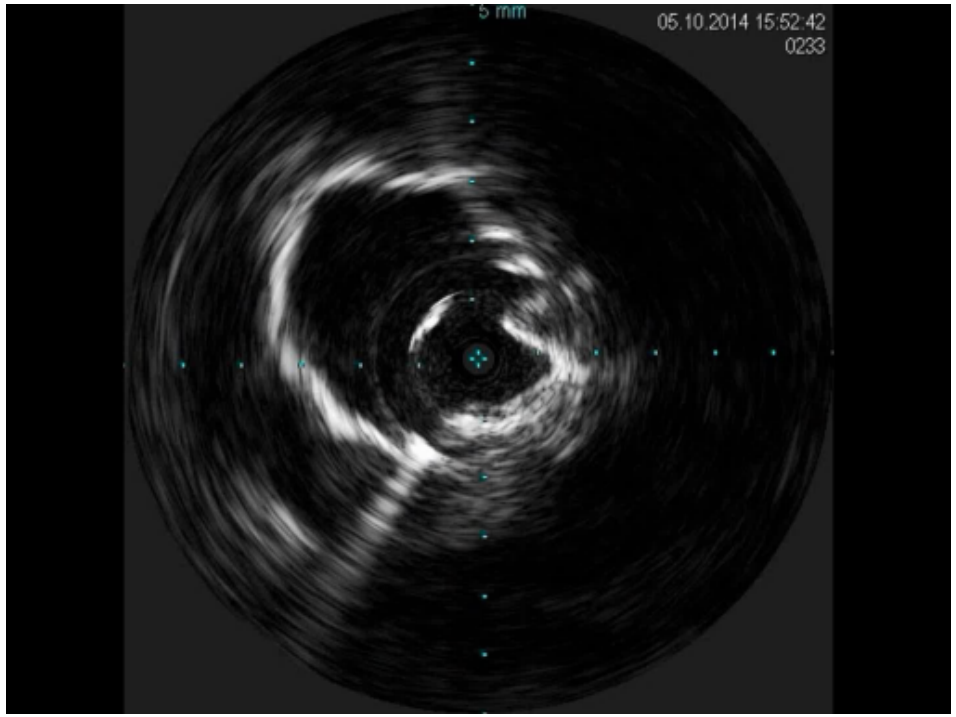

Sustained dynamic Malperfusion after FET

TEVAR - 2nd postop. day

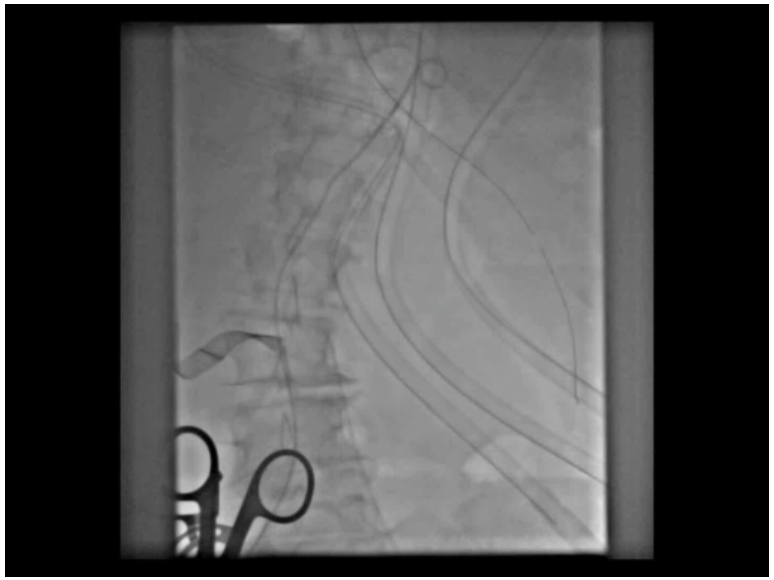

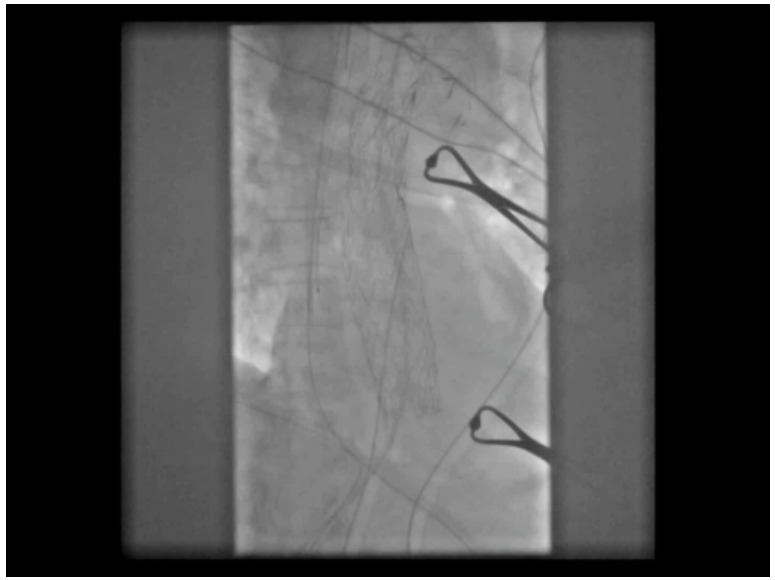

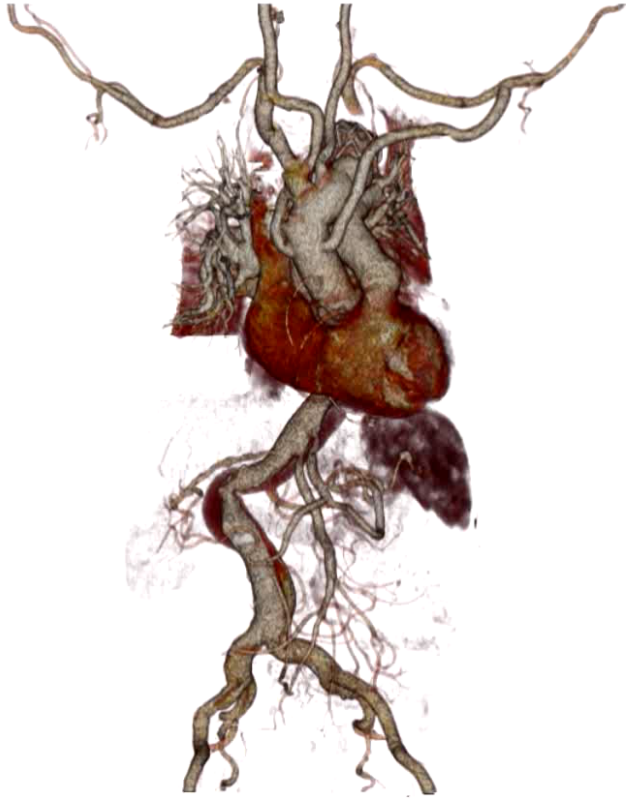

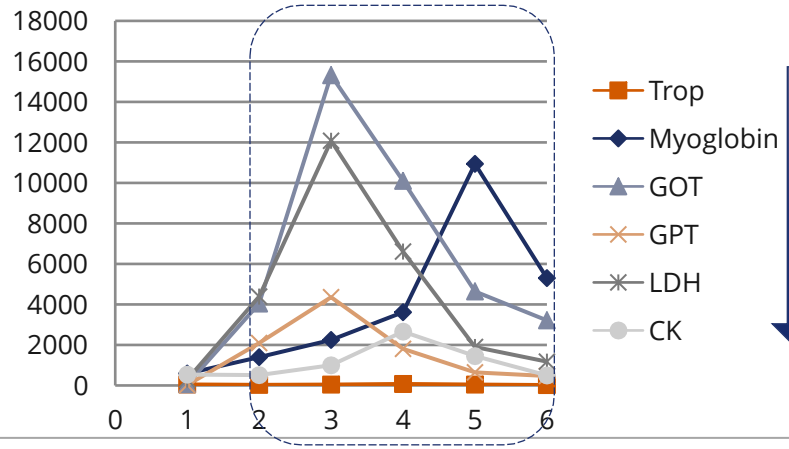

Explorative laparotomy (no mesenteric ischemia)
Hospital stay 17 days

Combination of Surgery with Endovascular Diagnostics/Treatment in Hybrid-OR

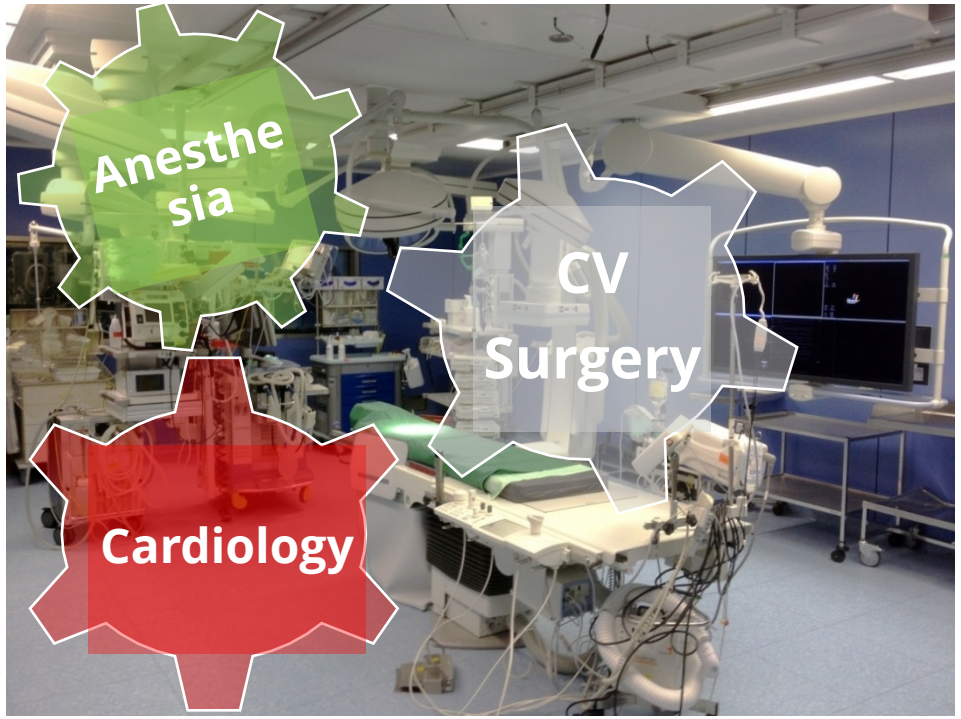

Endo + Surg. on the same table – no patient transport

Rationale of Hybrid OR Concept
Angiography for on time detection of dissection extent and malperfusion [coronary, cerebral, visceral, peripheral]
Evaluation of coronary artery disease
Endovascular TL stabilization and restoration of organ perfusion
Guide wires placement to secure FET
Control angiography postop., if required

Tsagakis et al., European J Thoracic and Cardiovascular Surgery 2013

Thoracoabd. TL-Stabilization in acute AAD

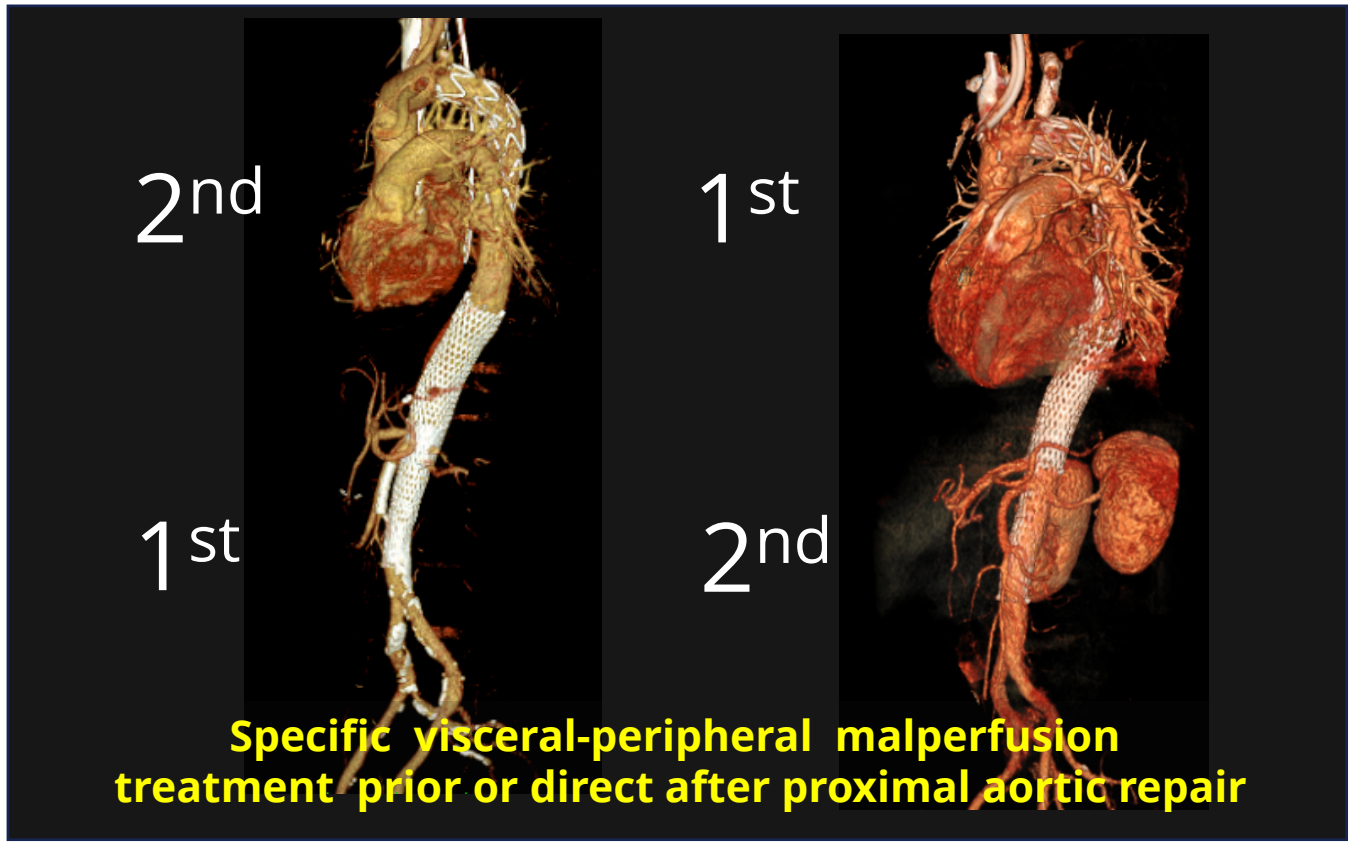

Tsagakis K, et al. Semin Thorac Cardiovasc Surg. 2019 Winter;31(4):740-748.

Combined Open and Endo Treatment in Hybrid –OR for AAAD

67yrs, female, Tamponade, TL collapse, Visceral + Peripheral Mal.

Treatment

- 1st - Restoration of splachnic/peripheral perfusion
- 2nd – Poximal ao. repair

- To avoid malperfusion during the cardiopulmonary bypass
- To reduce/avoid the metabolic disorder

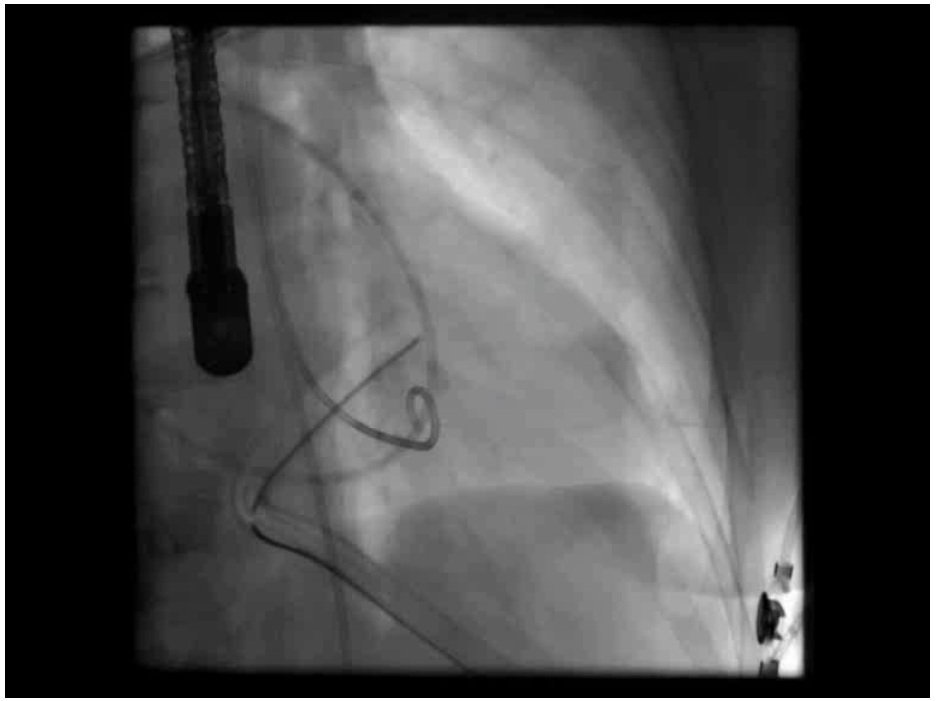

Pericardial Drainage + EVAR prior to Surgery

5 years FU

Experience with uncovered Stents in acute AD

N = 19 patients 2008-2018
30d Mortality 16.7%
FU mean 2.8 years

- No occlusion of visceral arteries
- No nitinol fracture
- Diameter abdominal aorta
  Enlargement (p=0.027)
  0.8 mm / year
- Area ratio TL/AL, %
  Stable (p=0.280)

→ No significant FL progress

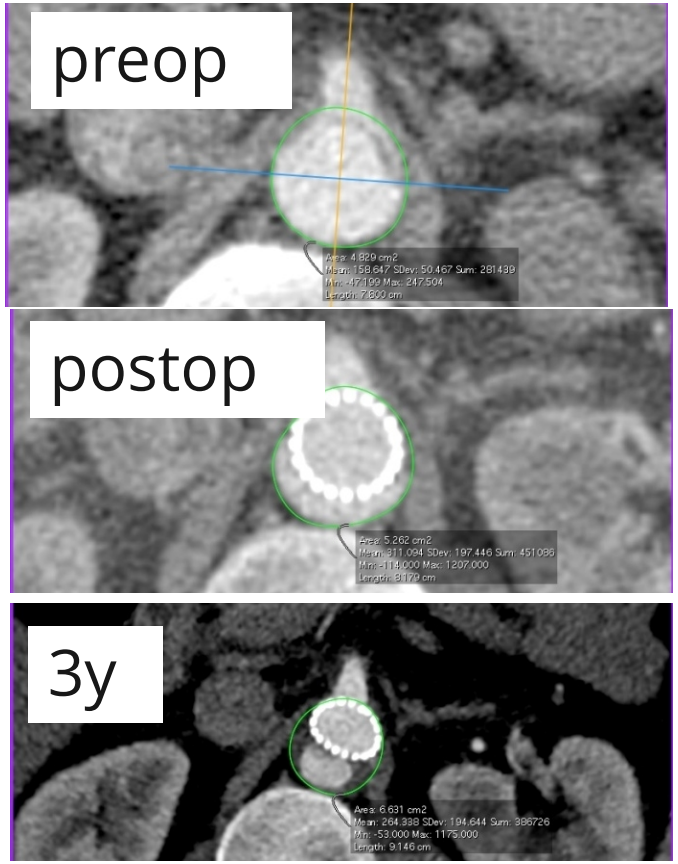

Tsagakis et al, Semin Thorac Cardiovasc Surg. 2019;31(4):740-748

Angioscopy for Extended Antegrade Treatment towards 1-staged repair of the aorta

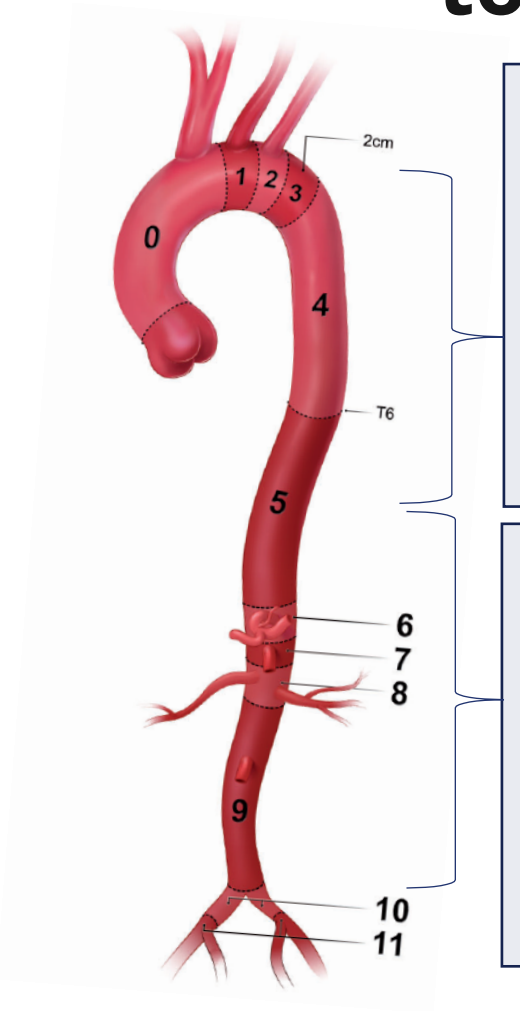

Thoracic aorta



FET

+

Stentgraft [GoreTAG]

Abdominal aorta

FET

+

Uncovered Stent [E-XL]

Endoscopically guided Treatment Downstream

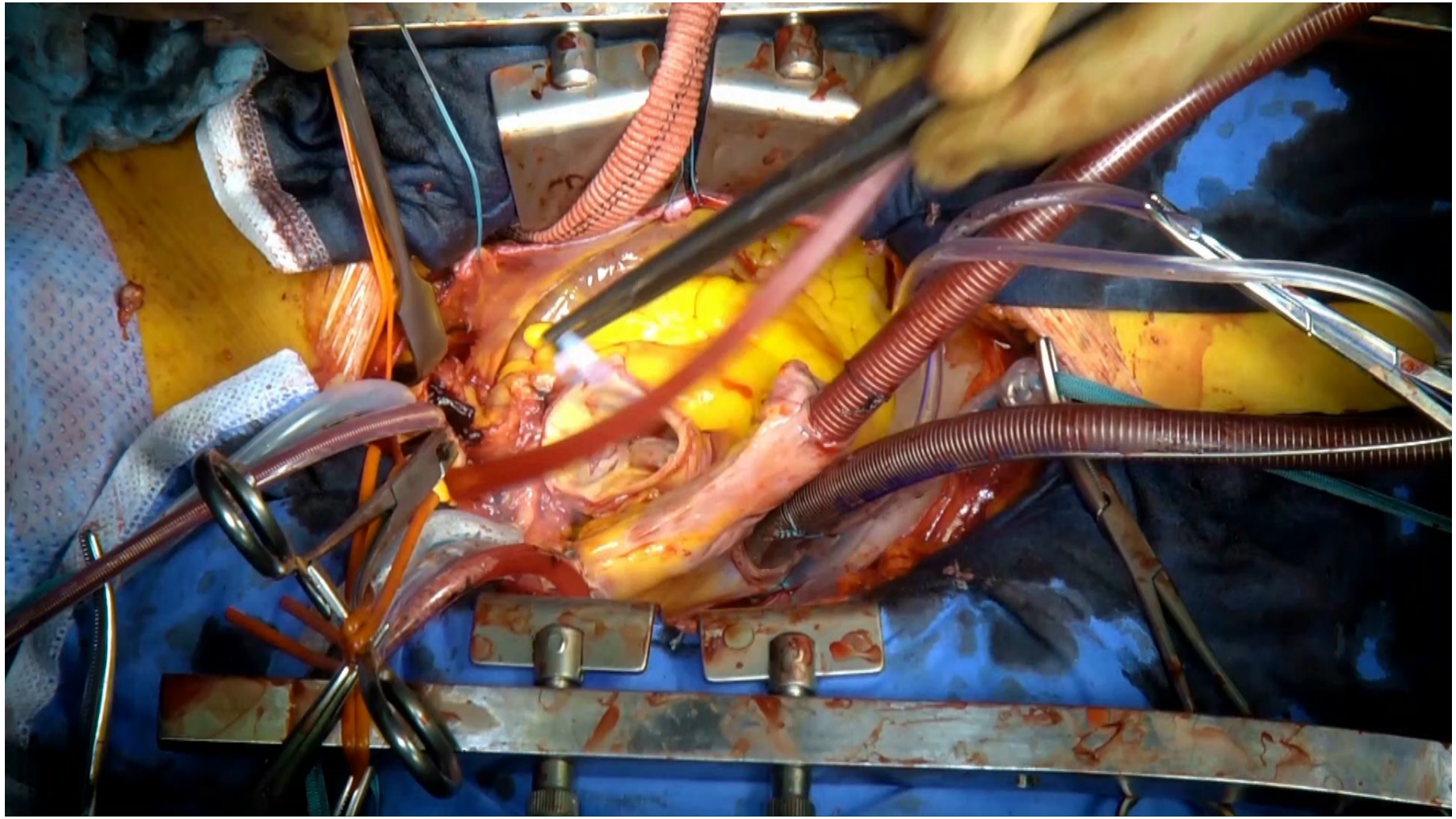

One-staged Treatment of the entire Aorta

<u>Surgery</u>
Partial root replacement
Ascending aorta replacement
FET
TL Stabilization (3 stents)

<u>Op-Times</u>
- CPB 268min
- Crossclamp 167min
- Visceral ischemia 63 min
- SACP 85min

<u>Postop. course</u>
Extubation after 12hours
Uncomplicated postop. course

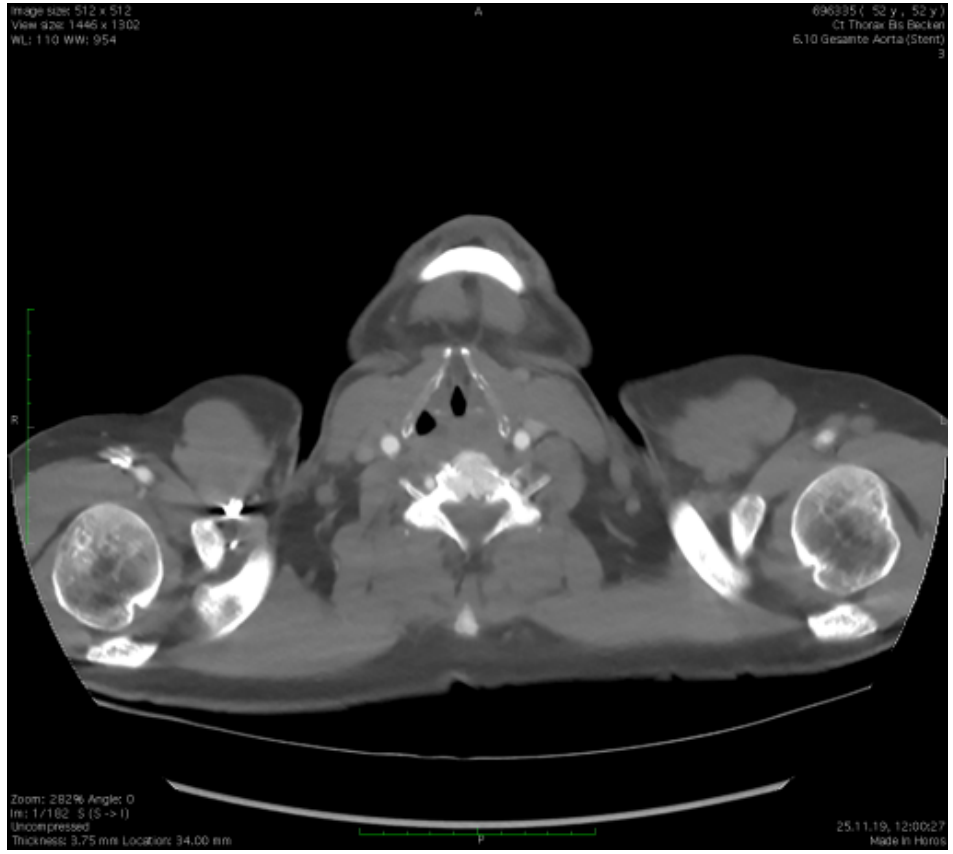

postop. CT

1 year FU

Exclusion of the entire False Lumen in 1-Stage

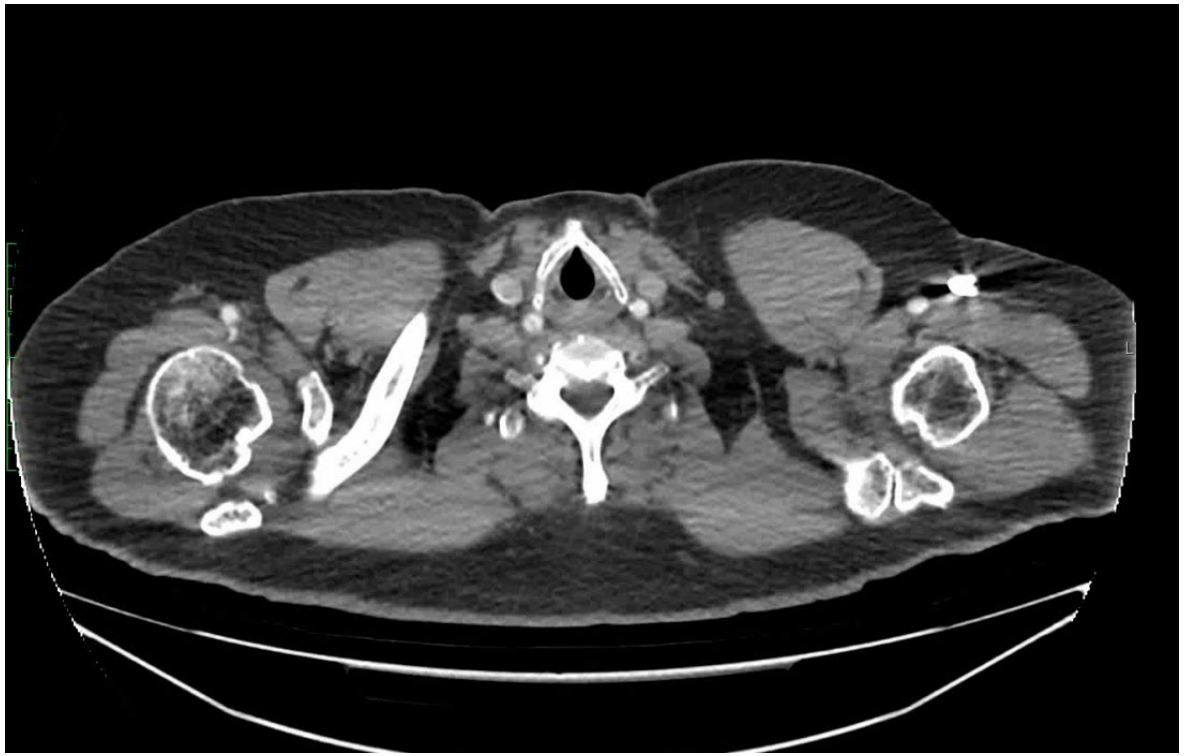

6 months after emergency surgery for acute Type I AD with Leriche Syndrome



The patient permitted the video presentation

Antegrade Treatment of the entire Aorta in acute AAD

2014-2022
30d Mortality 3/19 (16%)

Acute Type I AD	N = 18/19	
Thoracic aorta		
Obliteration	11 (61)	94%
Thrombosis	6 (33)	
Partial thrombosis	1 (6)	
Abdominal aorta		
Obliteration	6 (33)	39%
Thrombosis	1 (6)	
Partial thrombosis	4 (22)	
Patent	7 (39)	

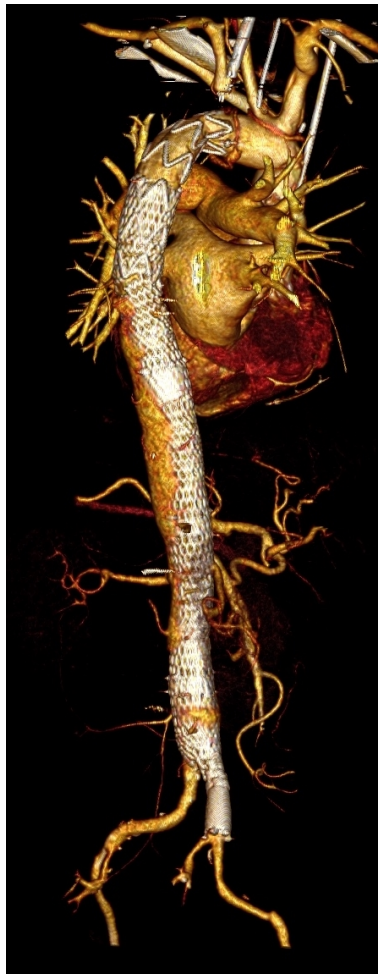

Acute Type A Aortic Dissection - Results

Essen Results, N = 534 AAAD

	Type II AD	Type I AD	p
30days Mortality	9.5%	17.4%	0.027

	Type I without distal malperfusion	Type I with distal malperfusion	p
30days Mortality	14.3%	23.6%	0.030

	Prox. ao. repair N=23	Extended ao. repair* N =100	p
30days Mortality	39.1%	20.0%	0.061

***Extended ao. repair: Frozen elephant trunk; ao. arch + desc. ao stenting; prox. repair+TEVAR**

Conclusions

- Visceral malperfusion represents the „major Killer“ in acute type A aortic dissection
- Hybrid suite allows for the evaluation of the visceral arteries perfusion and the simultaneous open and endovascular ao. repair, if required.
- Uncovered stents enable the stabilization of the true lumen downstream and improve the visceral perfusion
- The combination of proximal open aortic surgery with endovascular true lumen stabilization distally reduced the mortality and enabled the one stage treatment of the entire aorta in acute type I aortic dissection

© Universitätsmedizin Essen

konstantinos.tsagakis@uk-essen.de

Department of Thoracic and Cardiovascular Surgery

West German Heart and Vascular Center

University Hospital Essen, Germany